

Histological changes in liver and lungs of rats exposed to dichlorvos before and after vitamin supplementation

Olatunde Owoeye¹, Fabian V. Edem², Bukola S. Akinyoola², Sheu Rahaman², Effiong E. Akang³, Ganiyu O. Arinola²

1- Department of Anatomy, College of Medicine, University of Ibadan, Ibadan, Nigeria

2- Department of Chemical Pathology, College of Medicine, University of Ibadan, Ibadan, Nigeria

3- Department of Histopathology, University College Hospital, Ibadan, Nigeria

SUMMARY

This study evaluated the effect of vitamins with antioxidant activity on the effect of Dichlorvos (2, 2-dichlorovinyl dimethyl phosphate), an organophosphorus compound used in pest control on mammalian organs. Literature is scanty on the histopathological effects of inhalationally administered dichlorvos, especially of the formulations used in Nigeria. The objective of the study is to evaluate these effects on vital organs, with a view to proffering solutions to ameliorate the effects.

Fifty Wistar male rats were divided into 10 groups of 5 rats each. A group served as control, while the other groups were exposed to dichlorvos for between 1-6 weeks in a poorly ventilated compartment. The last three groups in addition to dichlorvos exposure received supplementation with vitamin C, E or red palm oil (RPO). Exposure to dichlorvos was done for 4 hours daily. At completion of exposure, animal tissue was processed by the routine method for paraffin wax and stained sections were examined under the light microscope.

Histopathological studies of the lung showed extension in the width of bronchial associated lymphoid tissue (BALT), mild generalized congestion of the peri-bronchiolar and inter-alveolar septum as compared with the control. These observations were much reduced in the vitamin-treated groups. Similarly, histopathological studies of the liver showed diffuse vacuolar degeneration of hepatocytes with peri-portal cellular infiltration by mononuclear cells, vacuolar degeneration and necrosis of hepatocytes when compared with the normal. These changes were significantly reduced in the vitamin-supplemented groups.

In conclusion, inhalationally absorbed dichlorvos caused histopathological changes in the lung and liver of rats, but these were ameliorated by co-treatment with vitamin supplementation. The changes provide the histological basis for further work and counselling on careful use of dichlorvos for domestic and agriculture, especially in enclosed areas.

Key words: Dichlorvos – Pesticide – Hepatic tissue – Histology – Vitamin supplementation

INTRODUCTION

In Nigeria, dichlorvos (2, 2 dichlorovinyl dimethyl phosphate), is used as a household and agricultural pesticide traded under names such as *Nuvan*, *Sniper* and *Ota-piapia*. Dichlorvos is used to control insects on crops, household, and stored products, and also to treat external parasitic infections in farmed fish, livestock, and domestic animals (Erdogan et al., 2007). *Ota-piapia* is particularly popular in Southern Nigeria, where it is commonly hawked around and used for agricultural and domestic purposes to kill various forms of insects and to protect stored products from insects. Musa et al., (2010) had reported that dichlorvos, a volatile organophosphate was the preponderant active pesticide ingredient in the local formulation of *Ota-piapia* from this region. Its popularity, acceptance, and widespread proliferation in Nigeria has been due solely to its cheap production, efficacy, accessibility, and affordability (Essiet, 2009). Dichlorvos (DDVP) has been in use since the early 1960s and has been the subject of many toxicity studies and review articles (Durkin and Follansbee, 2004). Dichlorvos is rapidly absorbed through the gastrointestinal and respiratory tracts and skin, it enters human system via inhalation, dermal, and oral routes, and it is metabolized by the liver and excreted by the kidney (Durkin and Follansbee, 2004; CERI, 2007). The mechanism of action for the organophosphates is mainly by blocking of acetylcholinesterase – an enzyme which decomposes acetylcholine (Lewalter and Korallus, 1986; Harlin and Dellinger, 1993). Being an acetylcholinesterase inhibitor, its overdose symptoms include weakness, headache, tightness in chest, blurred vision, salivation, sweating, nausea, vomiting, diarrhea, respiratory failure, and abdominal cramps (CEPA, 1996). It is mainly metabolized by esterase to dimethyl phosphate and dichloroacetaldehyde. Dimethyl phosphate is excreted in the urine, while dichloroacetaldehyde is rapidly metabolized via two pathways to dichloroethanol glucuronide, hippuric acid, urea and carbon dioxide, and excreted in the urine and expiration (CERI, 2007).

Studies support a role for reactive oxygen species (ROS) in the mechanism of dichlorvos toxicity (Sharma and Singh, 2012). Excessive generation of ROS causes irreversible impairment of DNA and damage to membrane

lipids during the production of malondialdehyde (Chan et al., 1991; Block et al., 2002; Gawel et al., 2004; Farombi et al., 2008; Arinola et al., 2011). Chan et al. (1991) reported that dichlorvos induced different types of neoplasms namely: adenomas of the exocrine pancreas, mononuclear cell leukaemia, and squamous cell papilloma of the forestomach in male and female Fischer rats and B6C3F1 mice. Fibroadenomas were also developed by in the mammary gland in female mice. Dichlorvos was similarly reported to damage DNA of insects in museum collections (Espeland et al., 2010). Previous studies also reported the toxicity of dichlorvos after oral or dermal administration on animal tissue (Luty et al., 1998; Desi and Nagymajtenyi, 1998), while literature regarding the effects of vitamin supplementation for the inhalational effect is scanty in this environment, and hence the need for this study. It was established that free radical generation was the basis of the toxicity of dichlorvos (Hai et al., 1997; Prakasam et al., 2001; Hsu et al., 2001; Sharma and Singh, 2012), the effect of antioxidants like ascorbic acid (vitamin C), alpha-tocopherol (vitamin E), and vitamin A as present in red palm oil (RPO) on the dichlorvos-treated rats will be evaluated. The study should answer the research question: can vitamin supplementation modify the histological alteration elicited by inhalational dichlorvos-induced toxicity in organs of Wistar rats?

MATERIALS AND METHODS

Experimental animals and treatments

This study was carried out using 50 eight week-old Wistar male rats (70.05 ± 6.25 g) procured from the Animal House of the Physiology Department, University of Ibadan, Nigeria. The animals were acclimatized to laboratory room conditions (12 hours dark – light period) for 2 weeks before being randomized into 10 groups of 5 rats per group as follows: unexposed group, six groups exposed to dichlorvos for 1 week, 2 weeks, 3 weeks, 4 weeks, 5 weeks and 6 weeks in a poorly ventilated compartment. Other groups were rats supplemented with either vitamin C (106 mg/kg body weight per oram per day), vitamin E (1.25 g/kg feed per day) or RPO (2 mL/25 g feed per day) daily in addition to

exposure to Dichlorvos21 for 5 weeks as detailed in Table 1.

Table 1. Grouping and treatment of experimental animals.

Groups	Treatment
1	Control: inhalation of room air for 4 hours/day for 1 week
2	Dichlorvos inhalation for 4 hours/day for 1 week
3	Dichlorvos inhalation for 4 hours/day for 2 weeks
4	Dichlorvos inhalation for 4 hours/day for 3 weeks
5	Dichlorvos inhalation for 4 hours/day for 4 weeks
6	Dichlorvos inhalation for 4 hours/day for 5 weeks
7	Dichlorvos inhalation for 4 hours/day for 6 weeks
8	Dichlorvos inhalation for 4 hours/day + Vitamin C for 5 weeks
9	Dichlorvos inhalation for 4 hours/day + Vitamin E for 5 weeks
10	Dichlorvos inhalation for 4 hours/day + RPO for 5 weeks

RPO = red palm oil.

The rats were fed with rat chow and water *ad libitum*. Dichlorvos (1000 mg/L) was purchased from an agrochemical shop in Ibadan, Nigeria, and then prepared in a dilution of 1:1 as recommended by the manufacturer (Hubei

Samonda Co. Ltd, China), i.e. 50 ml of dichlorvos was mixed with 50 ml of clean water. This preparation in a container was placed in a poorly ventilated compartment (carton with only one of the upper two lids partially opened). The rats' exposure to dichlorvos was done for 4 hours daily by the inhalational method by placing them into the cartons containing the preparation for the stated duration.

Sample collection and histological preparation

At completion of exposure, animals were anaesthetized with Ketamine anaesthesia (10 mg/kg intraperitoneally). Thereafter, the liver and lungs of each animal were removed and fixed in 10% formalin, then dehydrated with grades of ethanol (70, 80, 90, 95 and 100%). Dehydration was then followed by clearing the samples in 2 changes of xylene. Samples were then impregnated with 2 changes of molten paraffin wax, then embedded and blocked out.

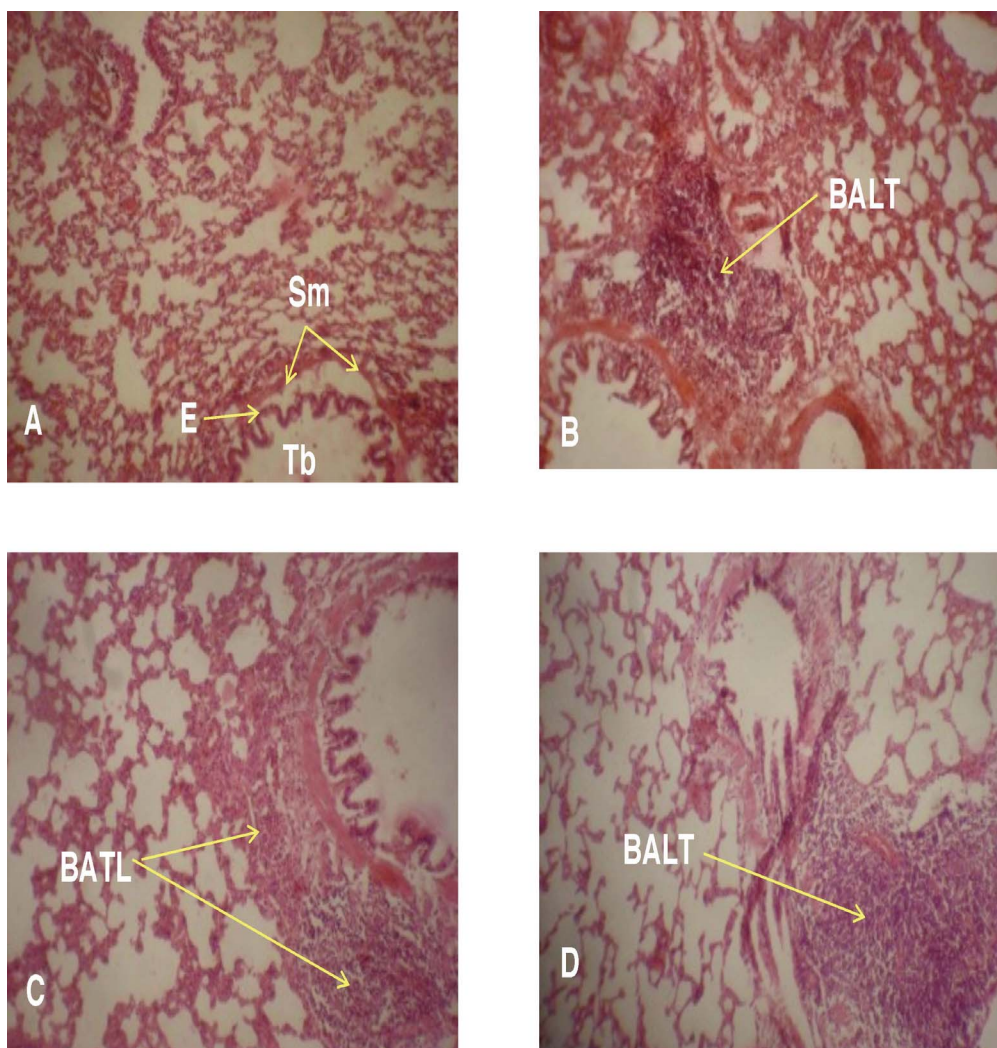


Fig. 1. Representative photomicrographs of lung of rats: A (control), B (exposed to dichlorvos for 1 week), C (exposed to dichlorvos for 4 weeks), D (exposed to dichlorvos for 5 weeks). H&E x 240. BALT – bronchial associated lymphoid tissue. Note the extensive BALT in B, C, and D. Tb – terminal bronchiole, Sm – smooth muscle, E – epithelium.

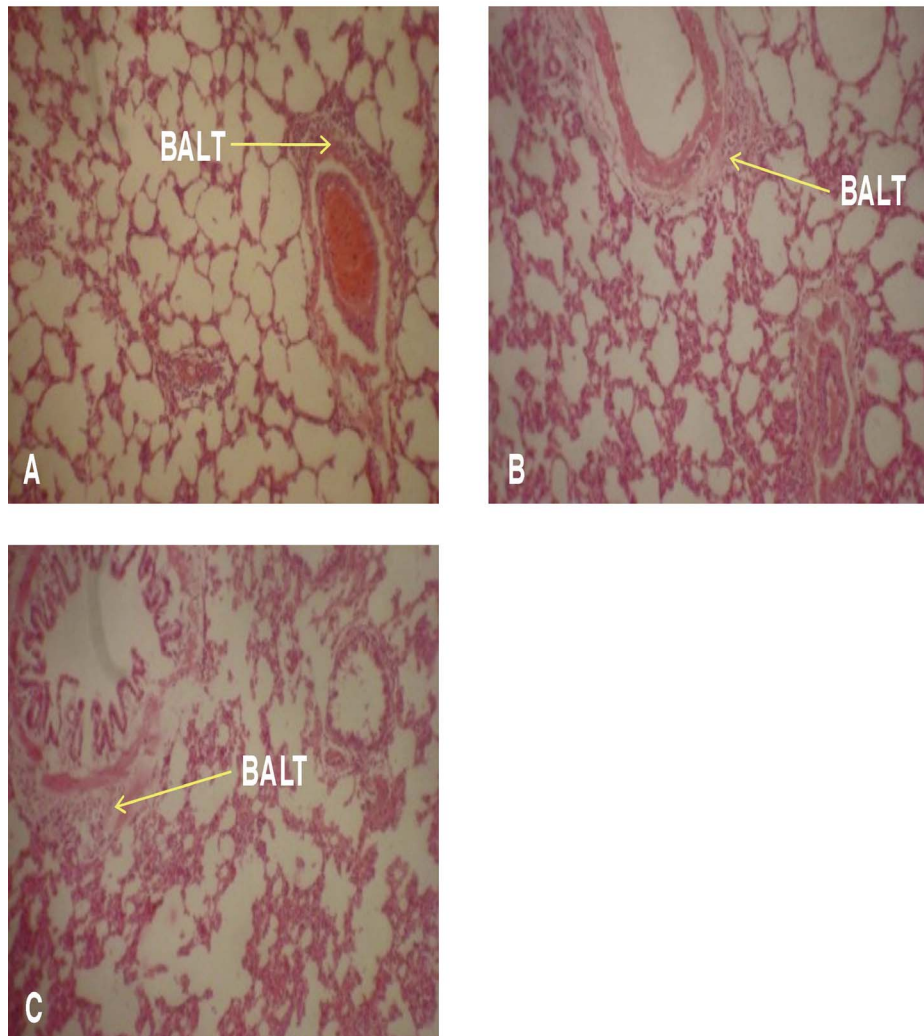


Fig. 2. Representative photomicrographs of lung of rats exposed to dichlorvos for 5 weeks. A (dichlorvos + Vit. C), B (dichlorvos + Vit. E), C (dichlorvos + RPO). H&E x 240. BALT – bronchial associated lymphoid tissue. Note the reduction in size of BALT in the vitamin - treated groups, viz. C, D, E when compared with the dichlorvos only groups in Fig. 1. RPO – red palm oil.

Paraffin sections (5-6 μm) thick transverse sections of the liver and the lung were cut using a rotary microtome and mounted on glass slides. The slides were stained with haematoxylin and eosin (H&E) according to Bancroft and Gamble, (2008). Stained sections of control and treated rats were examined under the light microscope (Olympus CH Japan) for alterations in the architecture of the lung, and that of the liver especially the portal tracts, hepatocytes, sinusoids, and for the presence of degeneration, necrosis, and portal fibrosis. Photomicrographs were taken with Sony DSC – W 30 Cyber – shot. All experiments were conducted in accordance with the guidelines approved by the University of Ibadan Ethical Committee.

RESULTS

(i) *Microscopic anatomy of the lung*

The microanatomy of the lung of control rats is shown in Fig. 1A. This photomicrograph shows a terminal bronchiole with the epithelium and the underlying strip of smooth muscle, in addition to the respiratory bronchiole, alveolar ducts, alveolar sacs and numerous alveoli separated by alveolar septum. This architecture was altered by the observation of an extension in the width of bronchial associated lymphoid tissue (BALT), in rats exposed to dichlorvos for 1 week (Fig. 1B) as compared with control rats which showed a normal structure (Fig. 1A). Similarly, there was a large prominent BALT observed in rats exposed for 4 and 5 weeks (Figs. 1C, 1D).

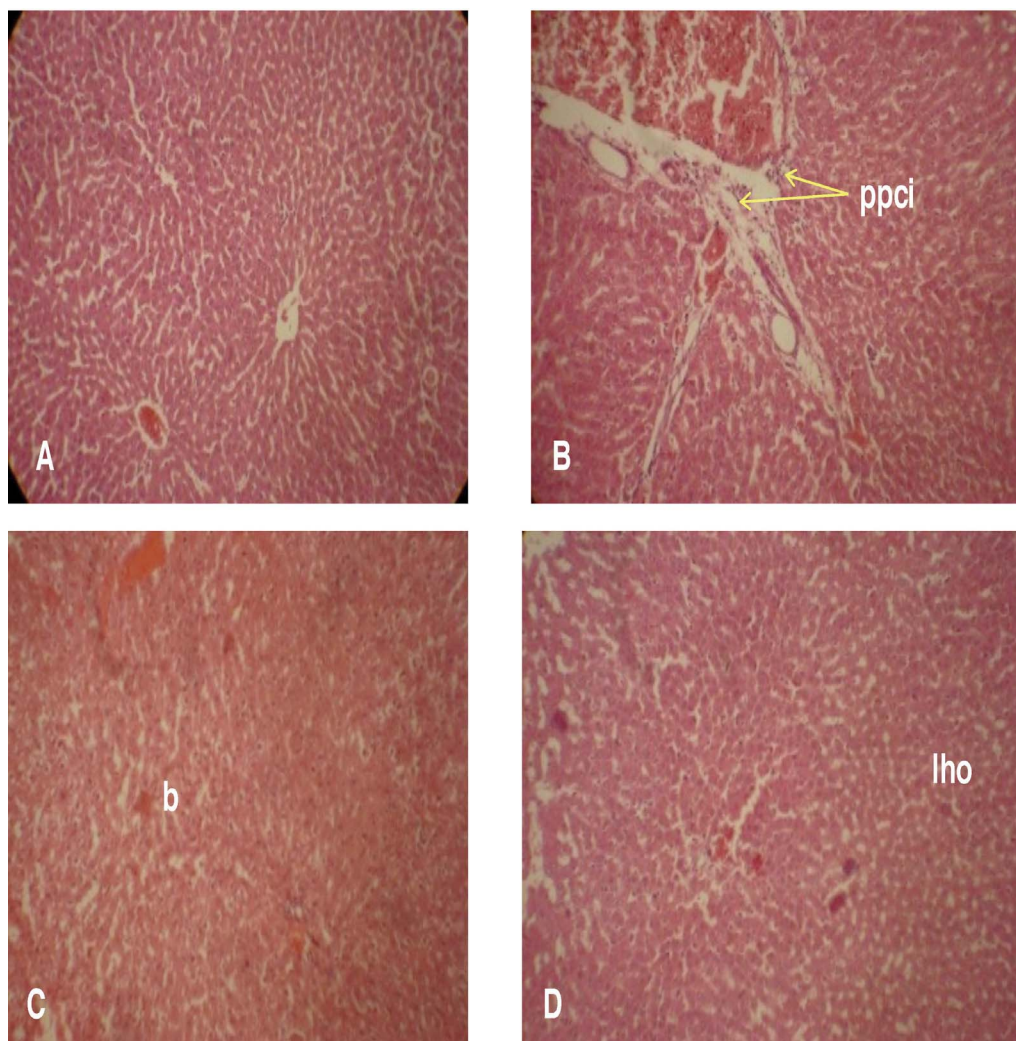


Fig. 3. Representative photomicrograph of liver of rats exposed to dichlorvos for 1, 2, 3 weeks. **A** (control), **B** (1 week exposure), **C** (2 weeks exposure), **D** (3 weeks exposure). H&E x 240. Periportal cellular infiltration (ppci), blurring of the trabecular structure of liver (b), loss of hepatocyte outline (lho) were observed.

These changes were reduced to near normal in the rats treated with vitamin supplements containing antioxidants as shown by the representative slides of the vitamin C- treated (Fig. 2A), vitamin E-treated (Fig. 2B), and the red-palm-oil-treated group (Fig. 2C) when compared to the dichlorvos-treated animals of Figs. 1B, 1C, 1D.

(ii) *Microscopic anatomy of the liver*

The liver of control rats (Figs. 3A, 5A) showed a normal structure with hexagonal lobules, central veins and peripheral triads embedded in connective tissue. The hepatocytes are arranged in trabecules running radially from the central vein and are separated by sinusoids, and each of the hepatocytes contains a large spheroidal nucleus. This microanatomical structure was altered as shown by the presence of the liver showing diffuse vacuolar degeneration of hepatocytes with necrotic

hepatocytes as well as moderate peri-portal cellular infiltration by mononuclear cells in rats exposed for 1 week (Fig. 3B) when compared with the control (Figs. 3A, 5A). There was a moderate to severe vacuolar degeneration and necrosis of hepatocytes (diffuse) in rats exposed for 2 weeks (Fig. 3C), while rats treated for 3 weeks showed loss of hepatocyte outline (Fig. 3D). In rats treated with dichlorvos for 4 weeks, the microanatomical alterations included: portal triads and vessels which were completely obscured and appeared circumscribed by fibrous connective tissue, necrotic plaques, periportal cellular infiltration, and diffuse necrosis as shown in Figs. 4A-4E). These histopathological changes were mitigated by rats treated with vitamin-supplementation as shown in (Fig. 5B) vitamins C, (Fig. 5C) vitamin E, and (Fig. 5D), RPO despite their concurrent exposure to dichlorvos.

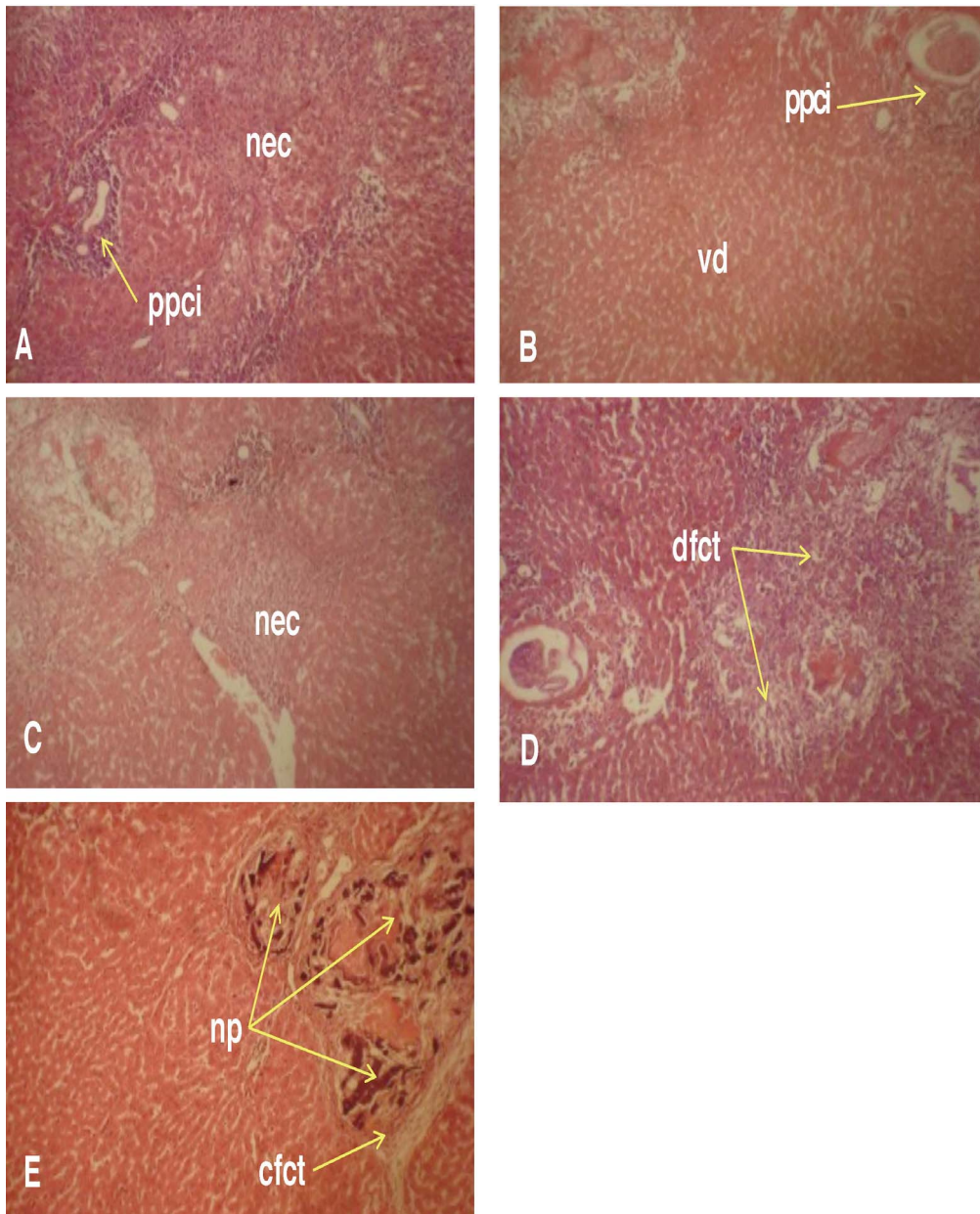


Fig. 4. Representative photomicrographs of liver of rats exposed to dichlorvos for 4 weeks. A, B, C, and D shows varying degrees of anatomical alterations ranging from vacuolar degeneration (vd) of hepatocytes, diffuse necrosis (nec), necrotic plaques (np), circumscribed fibrous connective tissue (cfct), diffused fibrous connective tissue (dfct), and periportal cellular infiltration (ppci). H & E x 240.

DISCUSSION

We observed the alteration in the microanatomy of the lungs as showed by the extension in the width of bronchial-associated lymphoid tissue (BALT) in rats exposed to dichlorvos through the inhalational route in our study. This did not agree with the observations in the lungs of rats treated with dermal absorption of dichlorvos for 4 weeks by Luty et al. (1998). The group reported the development of the widening of the intracellular septa with histiocytes of foamy as well as hyperemic foci of interalveolar septa and

extravasation to the lumen of lung alveoli in their study. The difference in the route of administration of dichlorvos might be responsible for this observed difference in our findings if compared with theirs. Nor did our findings agree with that of Blair et al. (1976), who in a similar inhalational study, reported that light microscopic examinations of the respiratory tract showed minor lungs changes that could not be correlated with exposure to dichlorvos. The increase in the amount of the lymphocytic reaction to the inhaled dichlorvos in our study is an indication of the measure of the integrity of the immune system's

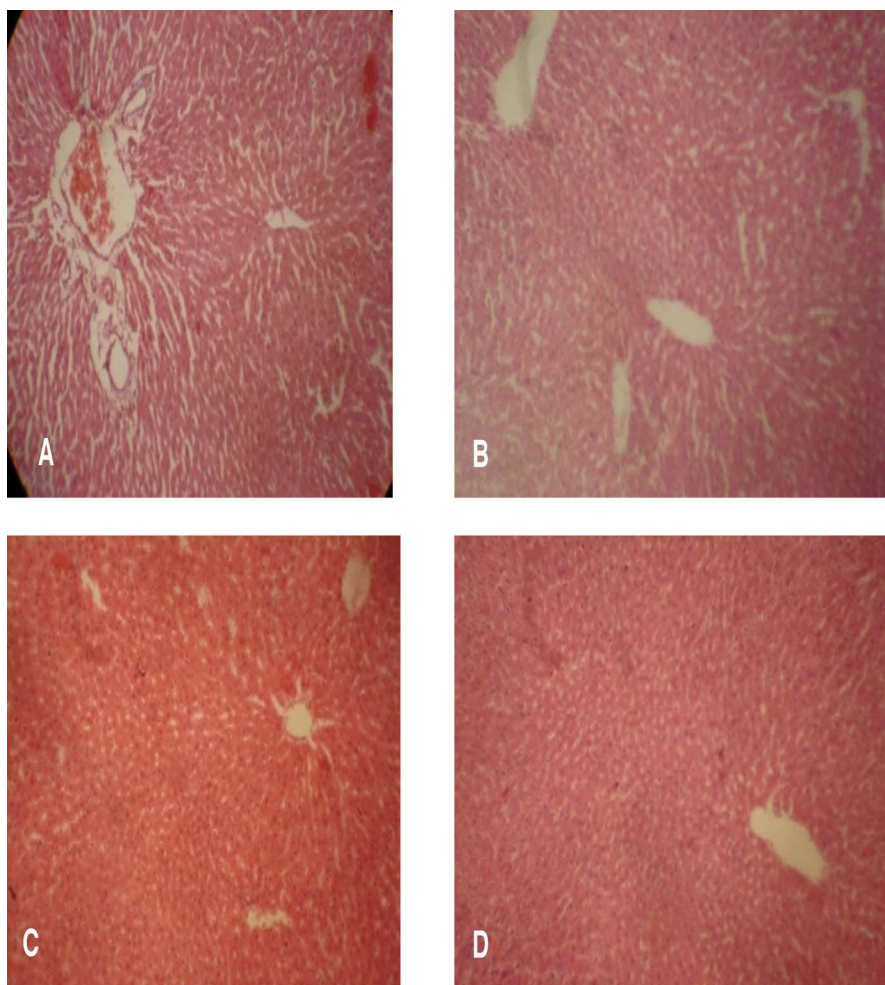


Fig. 5. Representative photomicrograph of liver of rats exposed to dichlorvos for 5 weeks. A (control), B (dichlorvos only), C (dichlorvos + Vit. C), D (dichlorvos + Vit. E), (dichlorvos + RPO). H&E x 240. Necrotic plaques, circumscribed fibrous connective tissue (cfct), diffused fibrous connective tissue (dfct), and periportal cellular infiltration (ppci) are absent. RPO – red palm oil.

response in these rats to the absorption of this volatile organophosphate.

Our report of alteration in the microanatomy of the liver of rats, showing the massive necrosis of hepatocytes with their replacement with fibrous tissue thus distorting the architecture of the portal tracts is an evidence of dichlorvos toxicity. Our findings was however, quite different from the reports of Luty et al. (1998), who reported an increase in the porosity of the cytoplasm in subcapsular hepatocytes at light microscopic level. While the difference in the route of absorption might be different in both studies, it would be expected that, since organophosphates are generally metabolized by the liver, the findings would be similar, which was not the case in our study. Dichlorvos pesticide causes toxicity in animals and humans (Sharma and Singh, 2012). Any toxic substance entering the body, like dichlorvos, would undergo biochemical transformation in the liver where it is detoxi-

fied by being metabolized. Overloading of the detoxification pathways leads to a build-up of toxins in the body leading to higher levels of free radicals, excess of which may damage the liver cells (Carbot, 2003). Functionally, the liver can be divided into three zones, based upon oxygen supply: the periportal (zone 1) hepatocytes of the hepatic acinus encircles the portal tracts where the oxygenated blood from hepatic arteries enter and are therefore more susceptible to the effects of blood-borne toxins than the midzonal (zone 2) hepatocytes and centrilobular (zone 3) hepatocytes similar to the distribution of iron in iron-overload (Özgüner and Sayin, 2002). The arrival of any toxic product like dichlorvos at the portal triads and the effect of its toxicity and its damaging effect will, expectedly, be more pronounced in zone 1 of the liver acinus (Brzoska et al., 2003). This might explain the pronounced effect observed in Figures 4A-4E. The effect should reduce towards the central

vein in zones 3 is located around central veins, where oxygenation is poor, but in this study, the other zones were not spared.

Dichlorvos is readily absorbed into the body of mammals via all routes of exposure, where it is rapidly metabolized and eliminated (Durkin and Follansbee, 2004). The nature and magnitude of the toxic effects produced by a given exposure to dichlorvos by any route are directly related to the dose and rate at which the exposure occurs. It may be safe to assume that the actual dose of dichlorvos in these local preparations are relatively high, hence the pronounced effect of the toxicity on the liver. The induced histological alterations in the liver of rats by dichlorvos might be an indication of injured hepatocytes due to its toxicity and also that of the liver's inability to deal with the accumulated residues resulting from its metabolic products (Abdelhalim and Jarrar, 2012). The appearance of hepatocytes degeneration and destruction leading to necrosis may be due to the generation of reactive oxygen species (ROS) generation by dichlorvos (Sharma and Singh, 2012), which in turn might have induced oxidative stress in the hepatocytes causing them to undergo necrosis.

The near reversal to normal histological features in the lungs and liver of rats treated with antioxidant-containing vitamin supplements as shown by the representative slides of the vitamin treated groups suggest that antioxidants actively reduced the reported oxidative damage caused by free radical generation by organophosphate toxicity (Prakasami et al., 2001; Hsu et al., 2001; Hai et al., 1997; Xiaolan et al., 2010). It is conceivable that the microanatomical alterations observed in the lungs and liver of the exposed rats was due to the toxicity induced by dichlorvos administration (Sharma and Singh, 2012). The antioxidant capacity of the vitamins co-administered with dichlorvos has been clearly demonstrated by the mitigation of the damage observed in the lungs and liver of these animals. It is, however, worthwhile to note that the effect of dichlorvos was more deleterious on the liver (the organ of its metabolism) than the lung (the organ of its absorption), despite same duration of exposure.

We conclude from this study that inhaled dichlorvos caused demonstrable histopathological changes in liver than in lungs of rats which were ameliorated with

antioxidant containing vitamin supplementation. However, more histomorphological, biomedical, histochemical and ultrastructural investigations are needed to correlate these findings with the potential threat posed by the continuous exposure to dichlorvos as an insecticide used in pest control, especially in enclosed areas.

REFERENCES

- ABDELHALIM MAK, JARRAR BM (2012) Histological alterations in the liver of rats induced by different gold nanoparticle sizes, doses and exposure duration. *J Nanobiotechnology*, 10: 5.
- ARINOLA OG, AKINOSUN OM, OLANIYI JA (2011) Passive and active cigarette smoking: effects on the levels of antioxidant vitamins, immunoglobulin classes and acute phase reactants. *Afr J Biotech*, 10: 6130-6132.
- BANCROFT JD, GAMBLE M (2008) *Theory and Practice of Histology Techniques*, 6th edition. Churchill Livingstone Elsevier, Philadelphia.
- BLAIR D, DIX KM, HUNT PF, THORPE E, STEVENSON DE, WALKER AI (1976) Dichlorvos: A 2-year inhalation carcinogenesis study. *Arch Toxicol*, 35: 281-294.
- BLOCK G, DIETRICH M, NORKUS EP, MORROW JD, HUDES M, CAAN B, PACKER L (2002) Factors associated with oxidative stress in human populations. *Am J Epidemiology*, 156: 274-285.
- BRZÓSKA MM, MONIUSZKO-JAKONIUK J, PILAT-MARCINKIEWICZ B, SAWICKI B (2003) Liver and kidney function and histology in rats exposed to cadmium and ethanol. *Alcohol Alcoholism*, 38: 2-10.
- CARBOT I (2003) The liver cleaning diet. Retrieved August 10, 2012 from <http://www.liverdoctor.com>
- CEPA: California Environmental Protection Agency (1996) Dichlorvos (DDVP) risk characterization document, medical toxicology and worker health and safety branches department of pesticide regulation California Environmental Protection Agency. California. CEPA, USA.
- CERI: Chemicals Evaluation and Research Institute (CERI), Japan (2007) Hazard assessment report on Dimethyl 2,2-dichlorovinyl phosphate. CAS no. 62-73-7.
- CHAN PO C, HUFF J, HASEMAN JK, ALISON R, PREJEAN JD (1991) Carcinogenesis studies of dichlorvos in Fischer rats and B6C3F1 mice. *Jpn J Cancer Res*, 82: 157-164.
- DESI I, NAGYMAJTENYI L (1988) Neurotoxicologic investigations of the pesticide dichlorvos (DDVP). Effects on the central and peripheral nervous system. *Toxicol*, 49: 141-148.
- DURKIN PR, FOLLANSBEE MH (2004) Control/eradication agents for the gypsy moth human, health and ecological risk assessment for DDVP (Dichlorvos). Syracuse Research Corporation, 301 Plainfield Road, Suite 350, Syracuse, New York 13212. Requisition No.: 43-3187-1-0269.
- ERDOGAN O, ATAMANALP M, SISMAN T, AKASAKI E, ALAK G (2007) Effects of 2, 2-Dichlorovinyl dimethyl phosphate (DDVP) on Hsp70 gene expression in rainbow trout. *Israeli J Aquaculture - Bamidgeh*, 59: 230-234.
- ESPELAND M, IRESTEDT M, JOHANSON KA, ÅKERLUND M, BERGH JE, KÄLLERSJÖ M (2010) Dichlorvos exposure impedes extraction and amplification of DNA from insects in museum collections. *Frontiers in Zoology*, 7: 2. doi:10.1186/1742-9994-7-2

- ESSIET D (2009) Making money from pest control business. *The Nation Newspapers, Nigeria*. www.thenationonline.net.
- FAROMBI EO, UGWUEZUMBA MC, EZENWADU TT, OYEYEMI MO, MARTINS E (2008) Tetracycline-induced reproductive toxicity in male rats: effects of vitamin C and N-acetylcysteine. *Exp Tox Pathol*, 60: 77-85.
- GAWEL S, WARDAS M, NIEDWOROK E, WARDAS P (2004) Malondialdehyde (MDA) as a lipid peroxidation marker. *Waid Lek*, 57, 9-10: 453-455.
- HAI DQ, VARGA SZI, MATKOVICS B (1997) Organophosphate effects on antioxidant system of carp (*Cyprinus carpio*) and catfish (*Italurus nebulosus*). *Comp Biochem Physiol*, 17C, 1: 83.
- HARLIN KS, DELLINGER JA (1993) Retina, brain and blood cholinesterase levels in cats treated with oral dichlorvos. *Vet Hum Toxicol*, 35: 201-203.
- HSU DZ, HSU CH, HUANG BM, LIU MY (2001) Abamectin effects on aspartate aminotransferase and nitric oxide in rats. *Toxicom*, 165: 189-193.
- LEWALTER J, KORALLUS U (1986) Erythrocyte protein conjugates as a principle of biological monitoring for pesticides. *Toxicol Lett*, 33: 153.
- LUTY S, LATUSZYNSKA J, HANINA H, TOCHMAN A, OBUCHOWSKA D, PRZYLEPA E, KORCZAK E, BYCHAWSKI E (1998) Toxicity of dermally absorbed dichlorvos in rats. *Ann Agric Environ Med*, 5: 57-64.
- MUSA U, HATI SS, MUSTAPHA A, MAGAJI G (2010) Dichlorvos concentrations in locally formulated pesticide (*Otapia*) utilized in northeastern Nigeria. *Sci Res Essay*, 5: 49-54.
- ÖZGÜNER M, SAYIN N (2002) Histological changes in rat liver after chronic iron-sorbitol overload. *J Ankara Medical School*, 24: 49-54.
- PRAKASAM A, SETHUPATHY S, LALITHA S (2001) Plasma and RBCs antioxidant status in occupational male pesticide sprayers. *Clinica Chimica Acta*, 310: 107-112.
- SHARMA P, SINGH R (2012) Dichlorvos and Lindane induced oxidative stress in rat brain: Protective effects of ginger. *Pharmacognosy Res*, 4: 27-32.
- XIAOLAN Z, WEIJUAN Y, BINBIN J, DAGONG S, WEIBO KA, DONGQI HE, XIFU W, ZONGYAO W (2010) Acute dichlorvos poisoning induces hemorheological abnormalities in rabbits via oxidative stress. *Clin Hemorheology and Microcirculation*, 44: 207-216.