

Virgin coconut oil and diabetic wound healing: histopathological and biochemical analysis

Amro M. Soliman, Teoh S. Lin, Norzana A. Ghafar, Srijit Das

Department of Anatomy, Universiti Kebangsaan Malaysia Medical Centre, 56000 Kuala Lumpur, Malaysia

SUMMARY

Delayed wound healing (the diabetic ulcer) is one of the major complications of diabetes mellitus (DM), which has shown an increasing trend over previous decades to affect almost 15% of diabetic patients. Virgin coconut oil (VCO) is a natural oil rich in vitamins and antioxidants and possesses antimicrobial and antiviral activities. In the current study, we evaluated the effects of topical application of VCO on wound healing in diabetes-induced *Sprague-Dawley* rats. A total of 72 animals were divided into 4 groups: i.e. (i) non-diabetic non-treated (NN), (ii) diabetic non-treated (DN), (iii) diabetic treated with VCO (VCO), and (iv) diabetic treated with silver sulfadiazine cream (SS). Wounds were inflicted on all groups using punch biopsy needles, and the animals were treated for 14 days. Wound closure rate (WCR) was measured on day 5, 10, and 14. Histological analysis was performed on day 7 and 14. Total protein content and superoxide dismutase (SOD) activity were measured on day 1, 7, and 14. WCR in VCO group was higher on all days compared to DN. Histological analysis revealed that VCO promoted re-epithelialization and increased collagen content of wound tissue. Total protein content in VCO group was higher on day 7 and 14 compared to both DN and SS groups. VCO showed insignificant effects on SOD levels. In summary, VCO was found to be better than silver sulfadiazine cream in the healing of diabetic wounds via promoting re-epithelialization and collagen synthesis as well as

increasing WCR and total protein content.

Key words: Diabetes – Healing – Virgin coconut oil – Wound

INTRODUCTION

Delayed wound healing (the diabetic ulcer) is considered to be one of the major complications of DM (ADM, 2014) which is commonly present in uncontrolled diabetic patients. The diabetic ulcer has shown an increasing trend over previous decades. In total, it is estimated that 15% of patients with diabetes would suffer from ulcers (Leone et al., 2012). A diabetic ulcer is reported to be a major source of morbidity and a main cause of hospitalization in diabetic patients (Aalaa et al., 2012; Shahbazian et al., 2013). It can lead to infection, gangrene, amputation, and even death in neglected cases (Snyder et al., 2009). Moreover, the diabetic ulcer is responsible for physical distress as well as productivity and financial losses, which lead to a severe economic burden (Vileikyte, 2001).

Wound healing is a complex process that runs through four sequential but overlapping phases: haemostasis, inflammation, proliferation, and remodeling (Reinke et al., 2012). DM causes delayed wound healing via several mechanisms: (i) angiogenesis disorders, in which there is a failure to develop new blood vessels in the wound area leading to poor oxygen and nutritional supply to the wound site (Brem et al., 2007); (ii) prolonged inflammation phase caused by inefficient immune system of diabetic patients (Edwards et al., 2004); (iii) destruction of extracellular matrix (ECM) including collagen and glycosaminoglycan by specif-

Corresponding author: Dr. Amro Mohamed Soliman. Department of Anatomy, Universiti Kebangsaan Malaysia Medical Center, Jalan Yaakob Latif, Bandar Tun Razak, 56000 Kuala Lumpur, Malaysia. Phone: (+6)011-12306811.

E-mail: dramrsoliman@yahoo.com

Submitted: 6 December, 2017. Accepted: 8 January, 2018.

ic enzymes as matrix metalloproteases (MMPs) (Bjarnsholt et al., 2008), and (iv) increasing oxidative stress and free radicals in addition to lowering levels of anti-oxidants (Maritim et al., 2003).

Virgin coconut oil (VCO) is a natural oil extracted from the mature kernel of the coconut fruit (*Cocos nucifera* L.) through different mechanical and natural methods (Mansor et al., 2012). VCO has plenty of health benefits due to the retained vitamins and antioxidants, as well as the antimicrobial and antiviral activities (Mansor et al., 2012). Its anti-inflammatory effects were observed in acute and chronic inflammation stages (Intahphuak et al., 2010). VCO was proven to have significant antioxidant effects (Yeap et al., 2015), including increasing levels of superoxide dismutase enzyme in the wound tissue of normal rats (Nevin et al., 2010). In the case of human chronic skin conditions such as xerosis and atopic dermatitis, VCO showed significant healing effects (Evangelista et al., 2014). Furthermore, VCO showed remarkable effects on wound healing of normal rats (Nevin et al., 2010). In the present research, the effect of topical application of VCO on diabetic wounds was observed. The results were also compared to the treatment with a conventional antibiotic cream, i.e., silver sulfadiazine cream.

MATERIALS AND METHODS

Animals

Seventy-two male *Sprague-Dawley* rats, weighing 150-250 g, were purchased from the Laboratory Animal Resource Unit, Faculty of Medicine, Universiti Kebangsaan Malaysia. They were kept in specially prepared metabolic cages at room temperature (23-28°C) with 12 hours light/12 hours dark photoperiod and 50% to 60% humidity in order to maintain normal circadian rhythm in the animal room. The rats were fed ad libitum with normal rat feed and water. Project protocol was approved by UKMAEC (Universiti Kebangsaan Malaysia - Animal Ethics Committee). The study was conducted in the Animal Lab, Department of Anatomy, Universiti Kebangsaan Malaysia Medical Center.

Experimental design

Animals were acclimatized under standard laboratory conditions for one week before the commencement of the experiment. Rats were divided into four main groups. NN group (n=18) is a normal group which is neither diabetic nor treated; DN group (n=18) is a diabetic non-treated group; VCO group (n=18) is a diabetic group treated topically with 1 ml of VCO daily for 14 days on daily basis; and SS group (n=18) is a diabetic group treated topically with silver sulfadiazine cream for 14 days on daily basis. In each group, six rats were sacrificed on day 1, 7, and 14. Wound tissue from sacrificed animals was collected for histological and biochemical analysis.

Induction of diabetes

Diabetes was induced in three groups (VCO, SS, and DN) by injecting the animals with a single dose (65 mg/kg) of streptozotocin (STZ) (Cayman Chemical, USA) intraperitoneally (Furman, 2015). Fasting blood glucose level was measured on the 3rd day after administration of STZ. Animals were considered diabetic if fasting blood glucose (FBG) was > 8 mmol/L (Furman, 2015).

Wound creation

On the day of the surgery (day 0), the rats were anesthetized with a combination of tiletamine and zolazepam (Zoletil 50; Virbac Laboratories, Carros, France). The thoracolumbar region of the rat was shaved to clear area for wounding. Four full-thickness skin excision wounds 6 mm in diameter were created using a punch biopsy needle 6mm in diameter (Fisher Scientific - USA), two on each side of the median line, approximately 20 mm from each other, and at a depth of about 1 mm on the dorsal aspect of the thoracolumbar region of all the animals.

Wound treatment

In the VCO group, each rat was treated topically with 1 ml of VCO (Bio-Asli, Malaysia) daily for 14 days. In the SS group, wounds were just covered with a layer (1/16 inch thickness) of silver sulfadiazine cream (according to the manufacturer's protocol) daily for 14 days. For the NN and DN groups, wounds were not treated. The wounds were left open during the entire experimental period.

Wound closure rate

Wound closure rate (WCR) was measured by serially photographing the wounds along with a scale (as a reference) using a digital camera (Coolpix 5400, Nikon, Japan) on day 5, 10, and 14 after wounding. The wound area was measured using image analysis software (ImageJ Software, USA). The following formula was used to calculate the rate of wound closure by using the initial and subsequent area of the wound during the experiment: % wound closure = [(day 0 area - day (n) area)/day 0 area] X 100, n = number of days (5, 10 or 14) (Kumar et al., 2008).

Histological analysis of wound tissue

Histological analysis of wound tissue on day 7 and 14 for all groups was performed. In order to obtain good sections for microscopy, the fixed tissues were first dehydrated to remove aqueous fixative and tissue water. Next, the tissue was cleared to remove the dehydrating agent. Finally, fixed skin specimens from each group were embedded in paraffin and sectioned using a microtome to be picked up on microscope slides. Slides were stained with Haematoxylin and Eosin (H&E) and Masson's Trichrome stains. Then, slides were mounted with neutral DPX medium and examined under a light microscope connected to an image

analyzer (Leica CTR.MIC., Germany) to capture images of the wound tissue. To evaluate the amount of collagen present in the wound tissue, we used ImageJ software to calculate the percent area stained by blue color which represents the collagen fibres using Masson's Trichrome stain (Foot, 1933). Based on a scoring system, the amount of collagen was graded semi-quantitatively according to the percent area which was stained with blue color on a five-tier scale where 0 = less than 10%, 1+ = 10–25%, 2+ = 25–50%, 3+ = 50–75%, 4+ = more than 75% (McDonald et al., 1999).

Total protein content

Wound tissue was collected using punch biopsy needles (same needles used to inflict wounds) to ensure collecting the wound tissue, not the normal skin. Then, 100 mg of wound tissue was homogenized in total protein extraction reagent (Thermo Scientific, USA). Total protein content of 72 samples was measured using Coomassie Plus (Bradford) Assay Kit (Thermo Scientific, USA) containing Coomassie Plus (Bradford) Assay Reagent; which contains coomassie G-250 dye, methanol, phosphoric acid and solubilizing agents in water; and Albumin Standard Ampules, 2 mg/mL, 10 × 1 mL ampules, containing bovine serum albu-

min (BSA) at 2.0mg/mL in a solution of 0.9% saline and 0.05% sodium azide. Coomassie dye binds protein in an acidic medium; an immediate shift in absorption maximum occurs from 465 nm to 595 nm with a concomitant color change from brown to blue. 10 µL of protein sample was added to the assay reagent, mixed well, and incubated briefly. Then, the absorbance was measured at 595 nm using a plate reader. Protein concentrations were estimated by reference to absorbance obtained for a series of standard protein dilutions, which were assayed alongside the unknown samples.

Superoxide dismutase level

An amount of 100 mg of wound tissue was added to 1 ml of cold PBS solution. Then, tissue was homogenized using Bio-prep tissue homogenizer. Homogenized tissue was centrifuged at 1500 x g for 5 minutes at 4°C to pellet tissue debris. The supernatant was collected and stored in -80°C freezer for subsequent downstream analysis. SOD activity in wound tissue for 72 samples on day 1, 7, and, 14 was evaluated. The assay was performed using superoxide dismutase assay kit (Cayman Chemical, USA) containing Assay buffer (50 mM Tris-HCl, PH 8.0, containing 0.1 mM hypoxanthine), Sample buffer (50 mM Tris-HCl, pH 8.0),

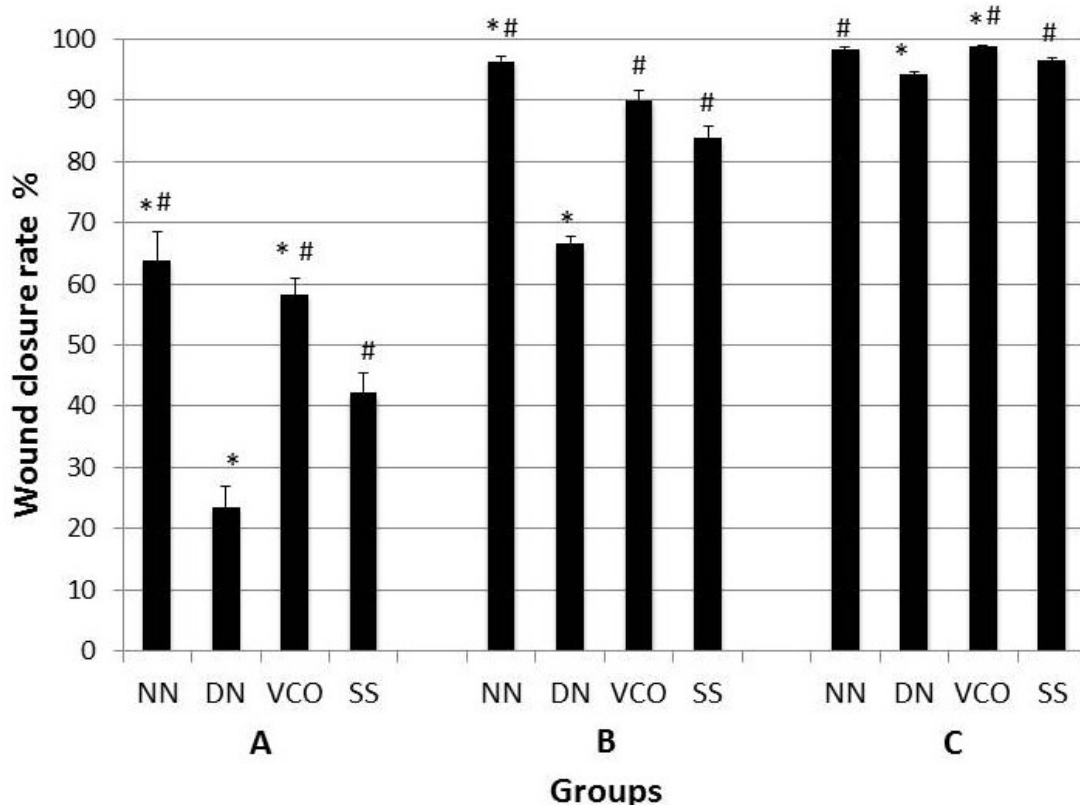


Fig 1. Wound closure rate (WCR) of all groups on day 5 (A), day 10 (B), and day 14 (C). WCR of VCO group was significantly higher compared to DN group on all days and to SS group on day 5 and 14 ($P < 0.05$). * indicates significant difference compared to SS group ($P < 0.05$). # indicates significant difference compared to DN group ($P < 0.05$). NN: non-diabetic non-treated group; DN: diabetic non-treated group; VCO: virgin coconut oil treated diabetic group; SS: silver sulfadiazine cream treated diabetic group.

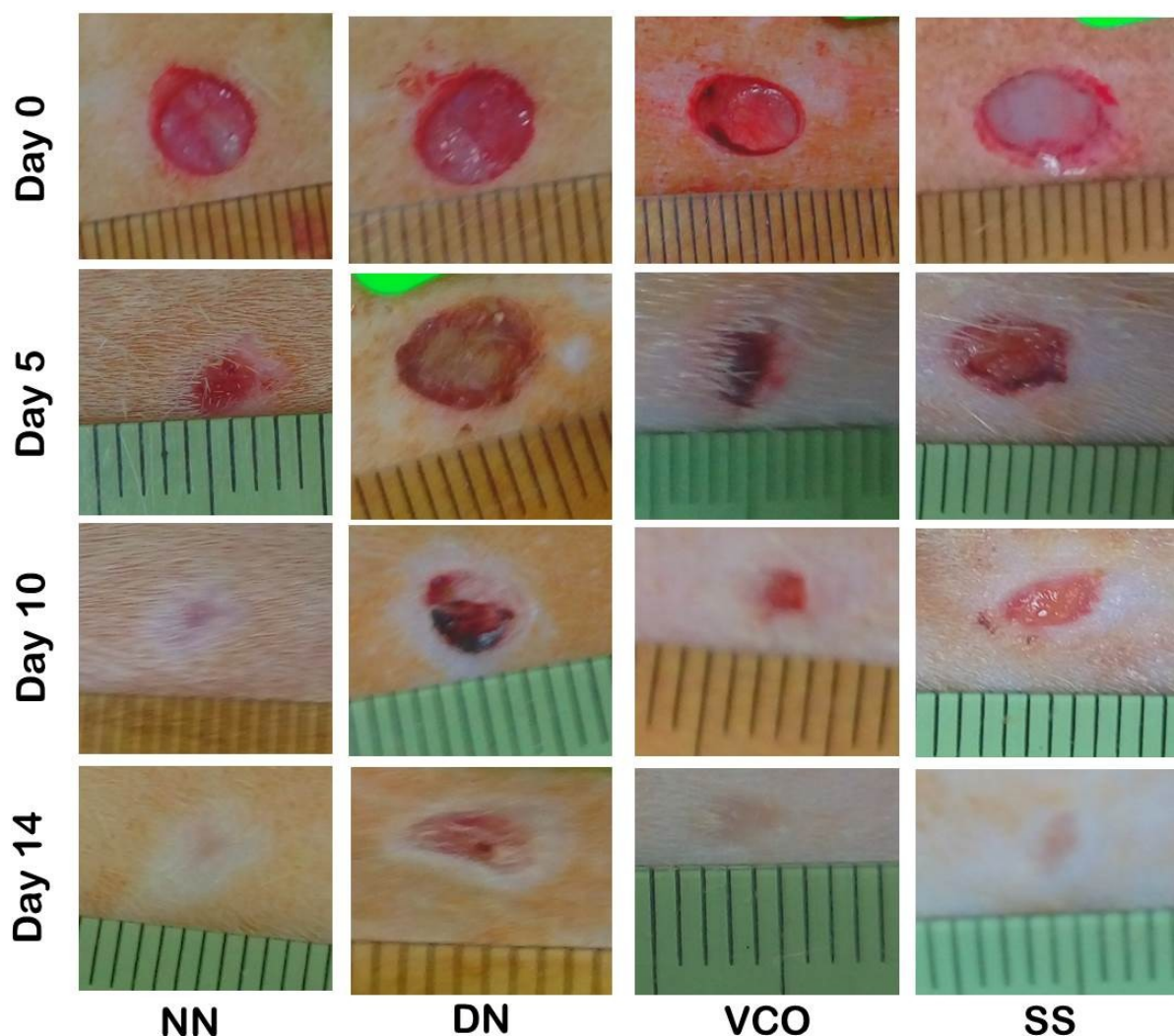


Fig 2. Macroscopic photographs of the wounds of all groups showing the closure progression of wounds on day 5, 10, and 14. NN: non-diabetic non-treated group; DN: diabetic non-treated group; VCO: virgin coconut oil treated diabetic group; SS: silver sulfadiazine cream treated diabetic group.

Radical detector containing tetrazolium salt solution, SOD standard solution containing 100 μ l of bovine erythrocyte SOD (Cu/ZN), and Xanthine oxidase enzyme. The tetrazolium salt detects the number of superoxide radicals generated by xanthine oxidase and hypoxanthine by converting it into a detectable dye measured by a plate reader at 440-460 nm. The more dye indicates more superoxide radicals, which in turn indicates lower SOD activity. The SOD activity of each sample was estimated by reference to absorbance obtained for a series of standard SOD dilutions, which are assayed alongside the unknown samples.

Statistical Analysis

The data were expressed as mean \pm standard error mean (SEM). The statistical analysis was performed using one-way analysis of variance (ANOVA) followed by Tukey's post hoc test. $P < 0.05$ was considered significant. All statistical analysis was performed using SPSS software

(version 22.0; SPSS Inc., Chicago, IL, USA).

RESULTS

After injection of animals with streptozotocin, there was an increase in FBG levels, reduction of body weight, an extensive water intake, and increased urine output. On day 3 after streptozotocin administration, rats were found to be hyperglycemic and their FBG levels remained high (23.49 ± 0.64 mmol/L) throughout the experiment compared to normal FBG levels (4.87 ± 0.06 mmol/L) before STZ administration.

Wound closure rate. WCR in the VCO group was significantly ($P < 0.05$) higher compared to both DN and SS groups on day 5 and 14 as well as to DN group on day 10. SS group showed significant ($P < 0.05$) higher WCR on all days compared to DN group (Fig. 1). Macroscopic photographs of the wounds of all groups showing the closure progression of wounds through the experiment are shown

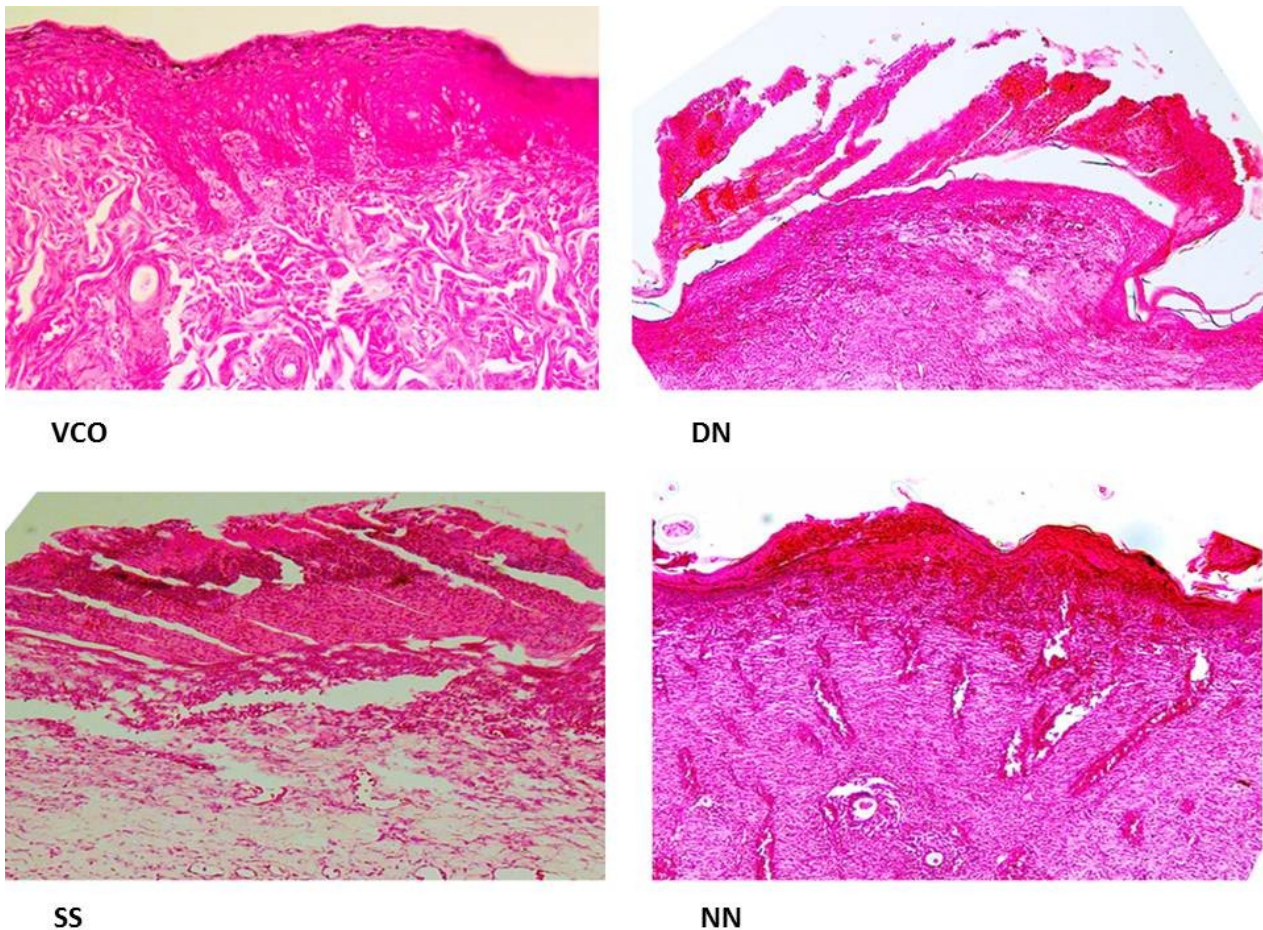


Fig 3. Skin wound on day 7 after wound creation. VCO and NN showing intact epidermis; VCO showing mature dermal papillae; SS and DN showing evident epidermal damage. VCO: virgin coconut oil treated diabetic group; SS: silver sulfadiazine cream treated diabetic group; DN: diabetic non- treated group; NN: non-diabetic non-treated group. Haematoxylin and eosin; original magnification x200.

in (Fig. 2).

Histological analysis. Histological analysis of wound tissue on day 7 revealed intact epidermis with developed dermal papillae in both VCO and NN group compared to the damaged epidermis in both DN and SS groups (Fig. 3). On day 7, VCO and NN groups showed high collagen content (3+ and 3+, respectively) (Fig. 4). While in DN and SS groups there was less collagen content (2+ and 1+, respectively) and more cellular infiltration (Fig. 4). On day 14, all groups showed complete epithelialization (Fig. 5). However, VCO group showed a fully mature epidermis with efficient dermal-epidermal interdigitation (Fig. 5). VCO and NN groups showed more collagen fibres (3+ and 3+, respectively) arranged in a very well-organized manner along with fibroblasts simulating the normal skin. On the other hand, the DN and SS groups showed a moderate amount of collagen (2+ and 2+, respectively) (Fig. 6).

Total protein content. The total protein content of wound tissue on day 1 was higher in VCO group compared to both DN and SS groups. However,

Values were not significantly different ($P>0.05$). Meanwhile, on day 7 and 14, wound tissue of VCO group showed significantly ($P<0.05$) higher total protein content compared to both DN and SS groups (Fig. 7).

SOD levels. SOD activity in wound tissue of NN group was insignificantly ($P>0.05$) higher on day 1, 7, and 14 compared to the other groups. On the other hand, SOD values of VCO, SS, and DN groups were insignificantly different ($P>0.05$) (Fig. 8).

DISCUSSION

Reduction of body weight of diabetic groups was noticed after STZ administration due to severe hyperglycemia experienced by the animals. WCR was measured as an indicator of the speed of wound healing. Previous studies measured the WCR as a significant parameter for wound healing (Qiu et al., 2007; Teoh et al., 2009). Other studies have reported that a delayed wound closure may cause worsening of wound healing and a faster

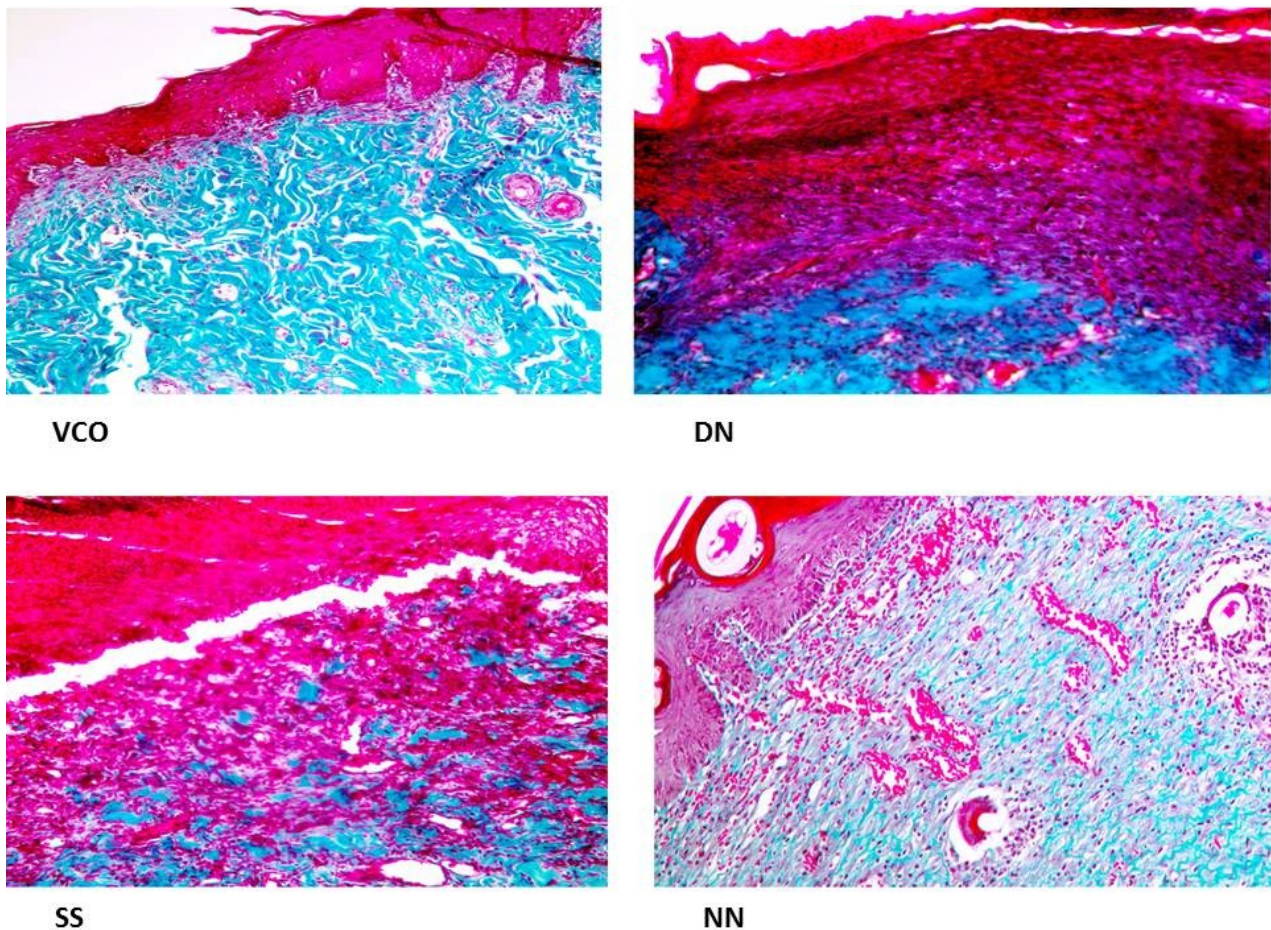


Fig 4. Skin wound on day 7 after wound creation. VCO and NN showing high collagen content (3+ and 3+, respectively) (blue color); SS and DN showing low collagen (2+ and 1+, respectively) and more cellular infiltration. VCO: virgin coconut oil treated diabetic group; SS: silver sulfadiazine cream treated diabetic group; DN: diabetic non-treated group; NN: non-diabetic non-treated group. Mason's Trichrome; original magnification x200.

wound closure enhanced the wound healing process (Jeffcoate et al., 2004). VCO and silver sulfadiazine enhanced wound healing of diabetic wounds by accelerating the WCR. However, VCO was proven to be significantly better than silver sulfadiazine cream. This may be attributed to the retained vitamins and antioxidants as well as the antimicrobial and antiviral activities of VCO (DebMandal et al., 2011; Mansor et al., 2012), which helps not only to eliminate bacteria but also to enhance the growth of wound tissue. On all days, NN group showed a significantly ($P < 0.05$) higher WCR compared to DN group. Previous studies reported a decreased WCR in diabetic rats compared to normal rats (Qiu et al., 2007; Teoh et al., 2009) which support our findings.

Histological analysis revealed that VCO promoted the re-epithelialization process. This could be explained by the intact epidermis and dermal-epidermal interdigitation that were observed in VCO group. This may illustrate the role of VCO in enhancing re-epithelialization process, which is considered a crucial step in wound healing (Serarslan et al., 2007). Previously, VCO was

found to promote and accelerate the re-epithelialization process in wound healing of normal rats (Nevin et al., 2010), which is in accordance with our results. On the other hand, wound tissue of DN group showed evident epidermal damage and absent dermal-epidermal interdigitation. Same findings were reported in a previous study (Teoh et al., 2009). Also, the damaged epidermis was observed in SS group, which may indicate the insignificant effect of silver sulfadiazine on the re-epithelialization process. On day 7 and 14, VCO group showed a higher content of collagen fibres compared to both SS and DN groups. The results may support the ability of VCO to induce collagen synthesis and deposition which was revealed by other studies (Nevin et al., 2010). Collagen is considered the major component of the ECM and its role in the wound healing process starts early after the skin injury and continues for many weeks (Shoshan, 1981). The low collagen content in DN group was found to be similar to the findings of a previous study (Dogan et al., 2017). This may be explained by the destructive effect of DM on the ECM caused by increased MMPs en-

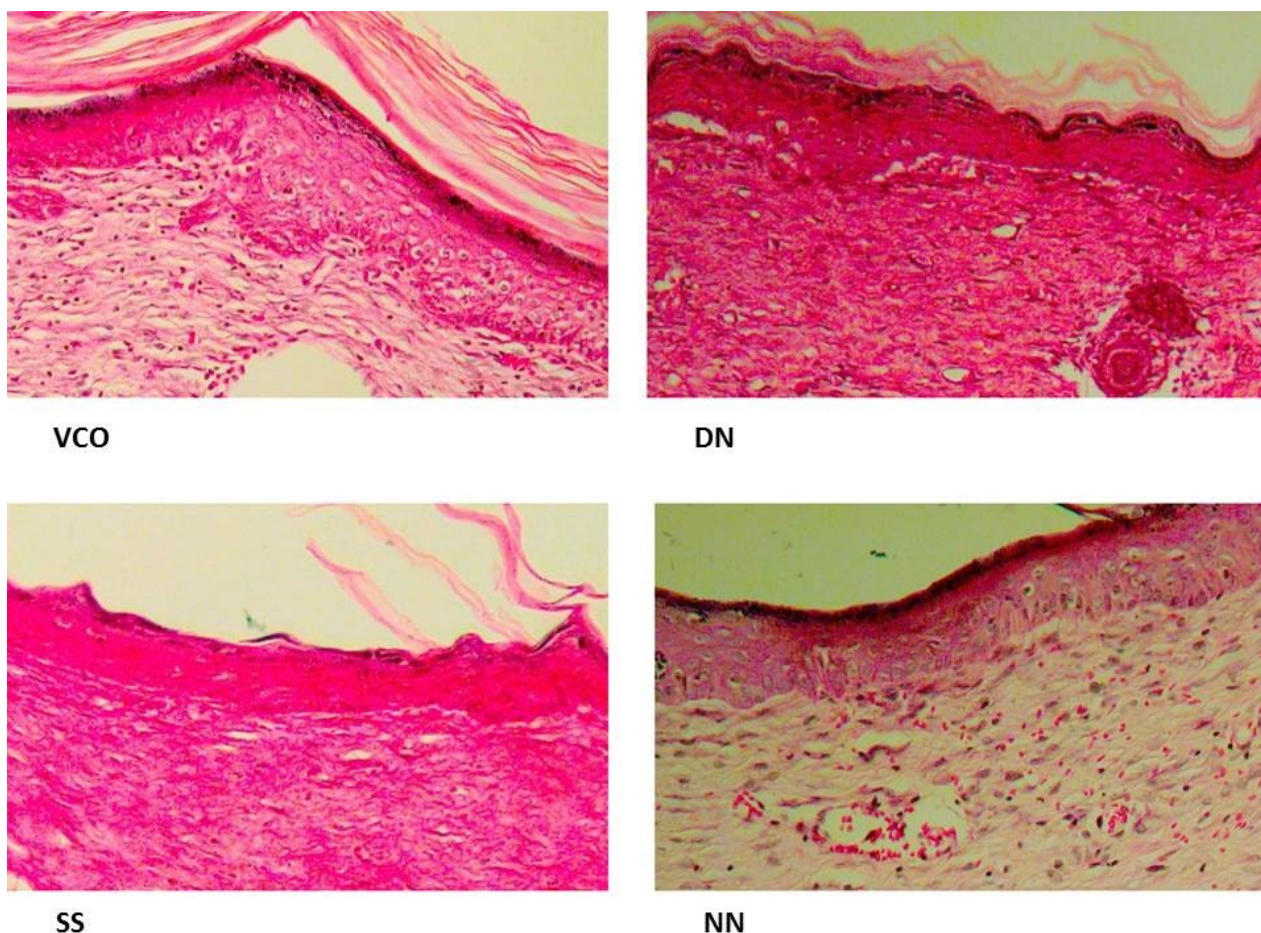


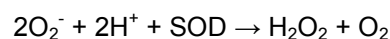Fig 5. Skin wound on day 14 after wound creation. All groups showing complete epithelialization; VCO showing interdigitation between epidermis and dermis. VCO: virgin coconut oil treated diabetic group; SS: silver sulfadiazine cream treated diabetic group; DN: diabetic non-treated group; NN: non-diabetic non-treated group. Haematoxylin and eosin; original magnification x200.

zymes in the wound tissue (Bjarnsholt et al., 2008). On day 14, the histological analysis of wound tissue of VCO group showed more new developed blood vessels compared to both DN and SS groups. The results suggest that VCO may have a role in promoting the angiogenesis process. Same findings were found in a previous study investigating the effects of VCO on wound healing (Ibrahim et al., 2013). Angiogenesis process is extremely vital for wound healing as it provides the essential oxygen and nutrients necessary for healing process (Li et al., 2003).

Different forms of proteins and amino acids were found to be essential in wound healing in terms of transporting trace elements, adhesion of regenerating tissue, the formation of ECM along with glycosaminoglycans (GAGs), organization of cellular elements, and inhibition of microbial invasion (Powanda et al., 1981). The total protein content of wound tissue in VCO group was significantly ($P < 0.05$) higher compared to the untreated groups and the silver-sulfadiazine-treated group. Increased total protein content in VCO group may indicate active synthesis and deposition of matrix

proteins (Sumitra et al., 2000). Same findings were reported by other studies (Nevin et al., 2010). Increased total protein content in the VCO group supports the high collagen content in wound tissue of VCO group detected by the histological analysis.

SOD is a metalloenzyme that catalyzes the dismutation of the superoxide anion to molecular oxygen and hydrogen peroxide and thus forms a crucial part of the cellular antioxidant defense mechanism (Boyer, 1976).



SOD is widely distributed through different tissues. However, it occurs in high concentrations in brain, liver, heart, erythrocyte, and kidney (Sandstrom et al., 1994). The amount of SOD present in the intracellular and extracellular environment is vital for the prevention of disease linked to oxidative stress (Maier et al., 2002). DM is associated with oxidative stress which increases the levels of free radicals and decreases the levels of antioxidants leading to more cellular damage and delayed wound healing (Maritim et al., 2003). DM

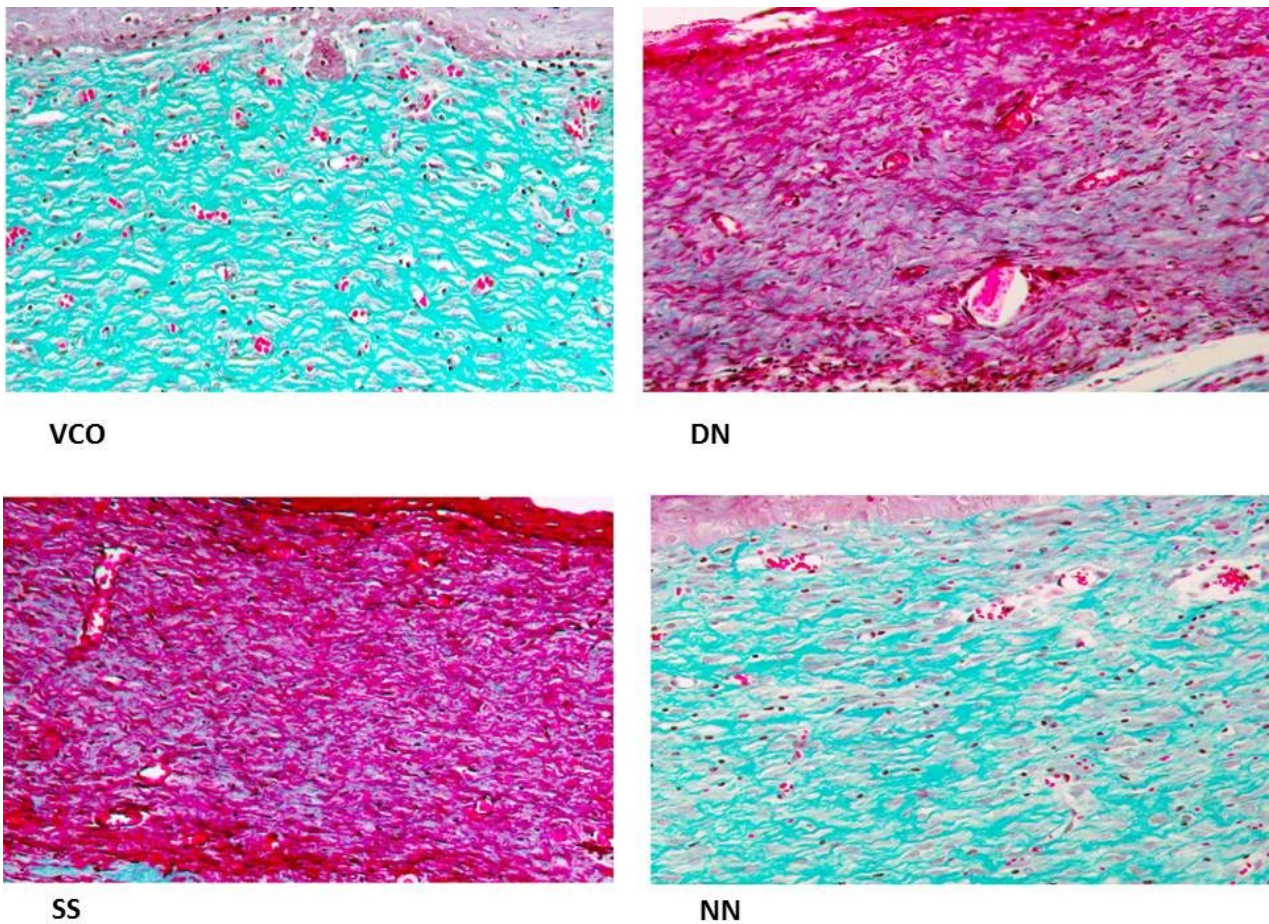


Fig 6. Skin wound on day 14 after wound creation. VCO and NN showing high collagen (3+ and 3+, respectively) fibres arranged in well-organized manner (blue color) compared to SS and DN which are showing low collagen content (2+ and 2+, respectively). VCO: virgin coconut oil treated diabetic group; SS: silver sulfadiazine cream treated diabetic group; DN: diabetic non-treated group; NN: non-diabetic non-treated group. Mason's Trichrome; original magnification x200.

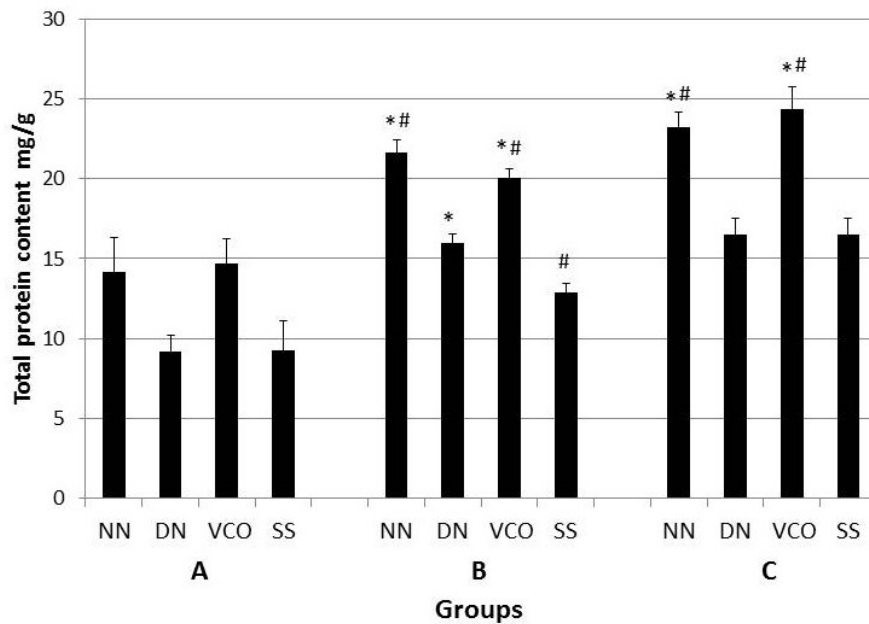


Fig 7. Total protein content in wound tissue of all groups on day 1 (A), day 7 (B), and day 14 (C). The total protein content of VCO group was significantly higher compared to both DN and SS groups on day 7 and 14 ($P < 0.05$). * indicates significant difference compared to SS group ($P < 0.05$). # indicates significant difference compared to DN group ($P < 0.05$). NN: non-diabetic non-treated group; DN: diabetic non-treated group; VCO: virgin coconut oil treated diabetic group; SS: silver sulfadiazine cream treated diabetic group.

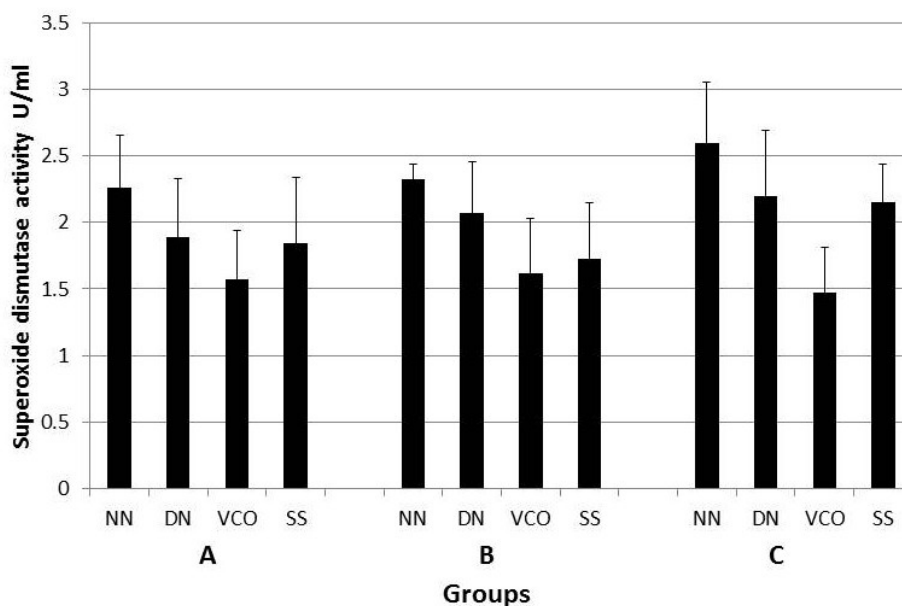


Fig 8. Superoxide dismutase (SOD) activity in wound tissue of all groups on day 1 (A), day 7 (B), and day 14 (C). VCO showed the insignificant effect on SOD level in wound tissue compared to both DN and SS groups on all days ($P < 0.05$). NN: non-diabetic non-treated group; DN: diabetic non-treated group; VCO: virgin coconut oil treated diabetic group; SS: silver sulfadiazine cream treated diabetic group.

was proven to reduce levels of SOD in different tissues such as skin (Jankovic et al., 2016) and retina (Kowluru et al., 2006) in diabetic animals. Results showed that SOD activity in the wound tissue of NN group was insignificantly ($P > 0.05$) higher on day 1, 7, and 14 compared to the other groups. This may support the role of DM in reducing levels of SOD in wound tissue (Jankovic et al., 2016). VCO showed insignificant effects on SOD levels. Previous studies showed that VCO exhibited antioxidant effects (Yeap et al., 2015) and it had a significant effect on SOD levels in the wound tissue of normal rats (Nevin et al., 2010). However, based on our literature review, no other studies have investigated the effect of VCO on the SOD levels in wound tissue of diabetic rats. Further investigations to evaluate the role of VCO as an antioxidant in diabetic wounds are recommended.

Conclusion

VCO showed significant effects on the wound healing of diabetic rats via increasing WCR and total protein content as well as enhancing collagen synthesis and re-epithelialization process. VCO was proved to be more significant than silver sulfadiazine cream in the healing of diabetic wounds.

ACKNOWLEDGEMENTS

The study was funded by UKM research grant. Thanks to all staff of Anatomy Department, Universiti Kebangsaan Malaysia Medical Center.

REFERENCES

- AALAA M, MALAZY OT, SANJARI M, PEIMANI M, MOHAJERI-TEHRANI M (2012) Nurses' role in diabetic foot prevention and care; a review. *J Diabetes Metab Disord*, 11: 24.
- ADM (2014) American Diabetes Association. Standards of medical care in diabetes-2014. *Diabetes Care*, 37: 14-80.
- BJARNSHOLT T, KIRKETERP-MOLLER K, JENSEN PO, MADSEN KG, PHIPPS R, KROGFELT K, HOIBY N, GIVSKOV M (2008) Why chronic wounds will not heal: a novel hypothesis. *Wound Repair Regen*, 16: 2-10.
- BOYER PD (1976) *The enzymes*. Academic Press, New York, London.
- BREM H, TOMIC-CANIC M (2007) Cellular and molecular basis of wound healing in diabetes. *J Clin Invest*, 117: 1219-1222.
- DEBMANDAL M, MANDAL S (2011) Coconut (*Cocos nucifera* L.: *Arecaceae*): In health promotion and disease prevention. *Asian Pac J Trop Med*, 4: 241-247.
- DOGAN E, YANMAZ L, GEDIKLI S, ERSOZ U, OKUMUS Z (2017) The effect of pycnogenol on wound healing in diabetic rats. *Ostomy Wound Manage*, 63: 41-47.
- EDWARDS R, HARDING KG (2004) Bacteria and wound healing. *Curr Opin Infect Dis*, 17: 91-96.
- EVANGELISTA MT, ABAD-CASINTAHAN F, LOPEZ-VILLAFUERTE L (2014) The effect of topical virgin coconut oil on SCORAD index, transepidermal water loss, and skin capacitance in mild to moderate pediatric atopic dermatitis: a randomized, double-blind, clinical trial. *Int J Dermatol*, 53: 100-108.

- FOOT NC (1933) The Masson trichrome staining methods in routine laboratory use. *Stain Technol*, 8: 101-110.
- FURMAN BL (2015) Streptozotocin-induced diabetic models in mice and rats. *Curr Protoc Pharmacol*, 70: 41-20.
- IBRAHIM A, AL-RAWI S, MAJID AA, AL-HABIB O, MAJID AA (2013) Pro-angiogenic and wound healing potency of virgin coconut oil. *Supp Care Cancer*, 21: 235.
- INTAHPHUAK S, KHONSUNG P, PANTHONG A (2010) Anti-inflammatory, analgesic, and antipyretic activities of virgin coconut oil. *Pharm Biol*, 48: 151-157.
- JANKOVIC A, FERRERI C, FILIPOVIC M, IVANOVIC-BURMAZOVIC I, STANCIC A, OTASEVIC V, KORAC A, BUZADZIC B, KORAC B (2016) Targeting the superoxide/nitric oxide ratio by L-arginine and SOD mimic in diabetic rat skin. *Free Radic Res*, 50: 51-63.
- JEFFCOATE WJ, PRICE P, HARDING KG (2004) Wound healing and treatments for people with diabetic foot ulcers. *Diabetes Metab Res Rev*, 20: 78-89.
- KOWLURU RA, ATASI L, HO YS (2006) Role of mitochondrial superoxide dismutase in the development of diabetic retinopathy. *Invest Ophthalmol Vis Sci*, 47: 1594-1599.
- KUMAR MS, KIRUBANANDAN S, SRIPRIYA R, SEHGAL PK (2008) Triphala promotes healing of infected full-thickness dermal wound. *J Surg Res*, 144: 94-101.
- LEONE S, PASCALE R, VITALE M, ESPOSITO S (2012) Epidemiology of diabetic foot. *Infez Med*, 20: 8-13.
- LI J, ZHANG YP, KIRSNER RS (2003) Angiogenesis in wound repair: angiogenic growth factors and the extracellular matrix. *Microsc Res Tech*, 60: 107-114.
- MAIER CM, CHAN PH (2002) Book review: role of superoxide dismutases in oxidative damage and neurodegenerative disorders. *The Neuroscientist*, 8: 323-334.
- MANSOR TST, CHE MAN YB, SHUHAIMI M, ABDUL AFIQ MJ, KU NURUL FKM (2012) Physicochemical properties of virgin coconut oil extracted from different processing methods. *Int Food Res J*, 19: 837-845.
- MARITIM AC, SANDERS RA, WATKINS JB, 3RD (2003) Diabetes, oxidative stress, and antioxidants: a review. *J Biochem Mol Toxicol*, 17: 24-38.
- MCDONALD JW, PILGRAM TK (1999) Nuclear expression of p53, p21 and cyclin D1 is increased in bronchioloalveolar carcinoma. *Histopathology*, 34: 439-446.
- NEVIN KG, RAJAMOCHAN T (2010) Effect of topical application of virgin coconut oil on skin components and antioxidant status during dermal wound healing in young rats. *Skin Pharmacol Physiol*, 23: 290-297.
- POWANDA MC, MOYER ED (1981) Plasma proteins and wound healing. *Surg Gynecol Obstet*, 153: 749-755.
- QIU Z, KWON AH, KAMIYAMA Y (2007) Effects of plasma fibronectin on the healing of full-thickness skin wounds in streptozotocin-induced diabetic rats. *J Surg Res*, 138: 64-70.
- REINKE JM, SORG H (2012) Wound repair and regeneration. *Eur Surg Res*, 49: 35-43.
- SANDSTROM J, NILSSON P, KARLSSON K, MARKLUND SL (1994) 10-fold increase in human plasma extracellular superoxide dismutase content caused by a mutation in heparin-binding domain. *J Biol Chem*, 269: 19163-19166.
- SERARSLAN G, ALTUG E, KONTAS T, ATIK E, AVCI G (2007) Caffeic acid phenethyl ester accelerates cutaneous wound healing in a rat model and decreases oxidative stress. *Clin Exp Dermatol*, 32: 709-715.
- SHAHBAZIAN H, YAZDANPANAH L, LATIFI SM (2013) Risk assessment of patients with diabetes for foot ulcers according to risk classification consensus of International Working Group on Diabetic Foot (IWGDF). *Pak J Med Sci*, 29: 730-734.
- SHOSHAN S (1981) Wound healing. *Int Rev Connect Tissue Res*, 9: 1-26.
- SNYDER RJ, HANFT JR (2009) Diabetic foot ulcers--effects on QOL, costs, and mortality and the role of standard wound care and advanced-care therapies. *Ostomy Wound Manage*, 55: 28-38.
- SUMITRA M, MANIKANDAN P, SUGUNA L, CEHITTAR G (2000) Study of dermal wound healing activity of *Trigonella foenum graecum* seeds in rats. *J Clin Biochem Nutr*, 28: 59-67.
- TEOH SL, LATIFF AA, DAS S (2009) The effect of topical extract of *Momordica charantia* (bitter melon) on wound healing in nondiabetic rats and in rats with diabetes induced by streptozotocin. *Clin Exp Dermatol*, 34: 815-822.
- VILEIKYTE L (2001) Diabetic foot ulcers: a quality of life issue. *Diabetes Metab Res Rev*, 17: 246-249.
- YEAP SK, BEH BK, ALI NM, YUSOF HM, HO WY, KOH SP, ALITHEEN NB, LONG K (2015) Antistress and antioxidant effects of virgin coconut oil in vivo. *Exp Ther Med*, 9: 39-42.