

Tanycytes in the human median eminence contain intestinal trefoil factor (hITF)

T. Griepentrog¹, M. Bauer², C. Hornstein², H. Sauer³ and G.F. Jirikowski¹

1- Institut für Anatomie, Anatomie II, Friedrich-Schiller-Universität Jena, Germany

2- Dept. of Neuropathology and General Psychiatry, Psychiatrisches Krankenhaus Wiesloch, Germany

3- Dept. of Psychiatry, Friedrich-Schiller-Universität Jena, Germany

SUMMARY

Human intestinal trefoil factor (hITF) has been localized in hypothalamic neuroendocrine cells, the adenohypophysis and the choroid plexus, indicating that hITF may represent a novel neuropeptide involved in various neural functions. In the present study, employing combined immunocytochemistry for hITF and with immunofluorescence for glial acidic fibrillary protein GFAP, we observed that a fraction of tanycytes in the human median eminence contain hITF. It is likely that hITF is of importance for the dynamics of blood-brain barrier functions, which are known to modulate neurosecretion in the neurohypophysial and the adenohypophysial tract within the median eminence.

Key Words: Tanycytes - human - median eminence - trefoil peptide - neuroglial interaction

INTRODUCTION

Human intestinal trefoil factor (hITF) is a member of the trefoil peptide - or P-domain family: it is characterized by a primary structure of six cysteine residues, a supersecondary configuration of three intrachain disulfide bonds, and a distinct tertiary structure (Podolsky et al., 1993). The peptide was first found to be present in the rat and human intestinal tract (Probst et al., 1995; Podolsky et al., 1993) and was later also detected

in the human hypothalamus and pituitary (Probst et al., 1996). Due to its biochemical properties hITF in the intestinal tract, it seems to be expressed in mucin-producing cells and in proliferating endothelial cells. The functional role of hITF in hypothalamic neurons or in the anterior pituitary lobe remains to be elucidated. Immunocytochemistry and in situ hybridization have demonstrated hITF immunoreactivity in fractions of magno- and parvocellular hypothalamic neurons, in the choroid plexus (Probst et al., 1996), in endocrine cells of the anterior pituitary, and in Herring Bodies of the neurohypophysis, suggesting that the trefoil peptide may have multiple functional properties, similar to many other neuropeptides. Tanycytes of the median eminence (ME) and pituicytes of the neural lobe are derived from the same glial precursor cells of the neuroectodermal matrix zone (Schiebler et al., 1978). Tanycytes line the bottom of the third ventricle. They are in close proximity to hypothalamic endocrine projections to the posterior pituitary lobe (Akmayev et al., 1973; Knowles, 1974). Infundibular tanycytes also extend towards the primary portal plexus and terminate with multiple processes in perivascular spaces of the median eminence (Löfgren, 1959; Wittkowski, 1968a). Thus, tanycytes establish a functional neuroglial link between the cerebro-spinal-fluid (CSF) and the portal system of the hypophysis. Tanycytes and pituicytes may be of some significance for the dynamics of the blood-brain barrier for the release of hypothalamic hormones. In this study we focused on the occurrence of human intestinal trefoil peptides in

Correspondence to:
Prof. Gustav F. Jirikowski, Institut für Anatomie / Anatomie II,
Friedrich-Schiller-Universität Jena, Teichgraben 7, D-07743 Jena, Germany.
Tel.: 0049 3641 938553; Fax: 0049 3641 938552. E-mail: gjir@mti-n.uni-jena.de

Submitted: July 12, 1999

Accepted: September 20, 1999

glial cells of the median eminence. We combined immunofluorescence for glial fibrillary acidic protein (GFAP) with immunoperoxidase staining for hITF in sections of human hypothalamus.

MATERIAL AND METHODS

Serial sections of 4 human hypothalami were provided by the Dept. of Neuropathology, Psychiatric Hospital at Wiesloch, Germany, from subjects without neuropathological history. Post-mortem time was between 6 and 18h. Tissue blocks were dissected and immersion-fixed in 6% paraformaldehyde in 0.1M phosphate buffer (pH 7.2) containing 0.9% sodium chloride (PBS) for a minimum of 7 days. 100 μ m thick serial sections were cut on a vibratome (Plano Instruments). Endogenous peroxidase activity was blocked by incubation of the sections in 10% methanol and 3% hydrogen peroxide for 15 min at room temperature. Sections were then immunostained for hITF with a rabbit antiserum at 4°C overnight, diluted 1:2000 in PBS containing 0.5% Triton-X (PBST). For details on the specificity and characterization of this antibody see Probst et al. (1995). Immunoprecipitates were visualized after 2x10 min washings in PBST with the peroxidase-anti-peroxidase method, as described earlier. Diaminobenzidine and hydrogen

peroxide were used to stain the immunocomplexes. For subsequent immunofluorescence, antibody precipitates of the first reaction were removed by incubating the sections in 0.1N HCl for 15 min. at room temperature. Sections were incubated with rabbit-anti-GFAP (Chemicon) at a dilution of 1:500 in PBST at 4°C overnight. After further washing steps in PBST, sections were treated with a Cy3 labelled anti rabbit IgG (Jackson Immuno Research Laboratory, Inc.) diluted 1:200 in PBST for 1h at room temperature. After additional washing in PBST, sections were affixed to slides, coverslipped with Moviol (Sigma). Immunocytochemical controls were carried out with either rabbit normal serum or antigen preabsorbed antisera at 0.1 g / 1ml PBS instead of the specific antibody. Evaluation of sections was performed with an Olympus photomicroscope using either interference contrast microscopy or epifluorescence (filterset WU).

RESULTS

Tissue preservation of the sections was exceptionally good due to the short postmortem time and the immediate fixation. All four patient samples showed similar immunoreactive patterns. hITF immunoreactivity was seen in the previously observed distribution within the magnocellular nuclei of the hypothalamus, the supra-

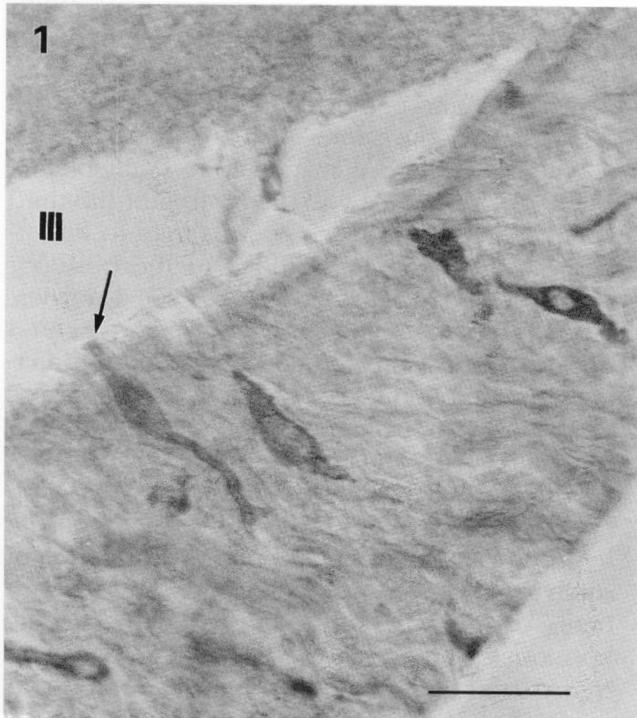


Fig. 1. hITF-immunoreactive cells represent a fraction of the tanycytes lining the third ventricle (III). These cells extend processes towards the ventricular lumen (arrow). Scale bar = 10 μ m.

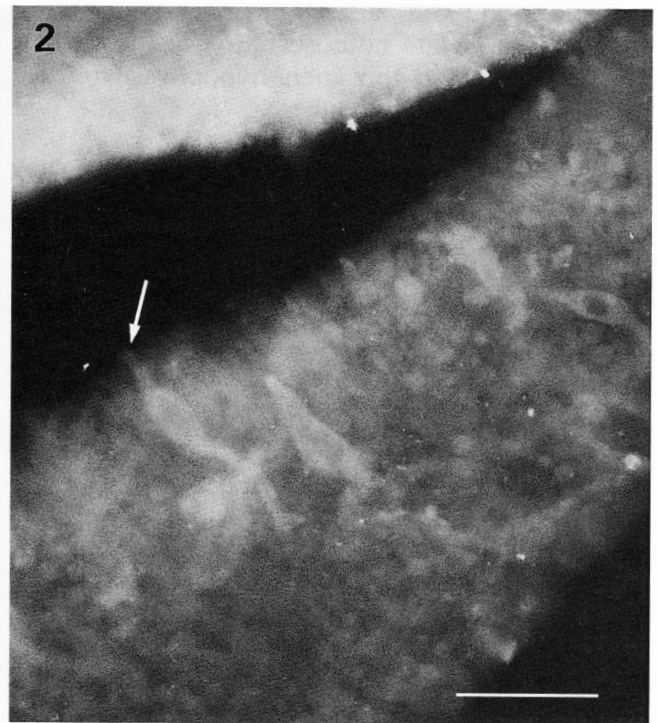


Fig. 2. All of the hITF-positive tanycytes show immunofluorescence for GFAP (arrow). Scale bar = 10 μ m.

optic nucleus (SON), and the paraventricular nucleus (PVN). hITF-positive cells also appeared in the accessory hypothalamic nuclei as well as in single neurons in the periventricular nucleus (PEV). hITF-positive neuronal perikarya were also observed in close apposition to blood vessels in the retrochiasmatic region of the hypothalamus. Furthermore, we found intense hITF staining in single cells of the median eminence and the infundibular stem of the hypothalamus (Fig. 1). In all cases staining was confined to the cytoplasm while the nucleus remained unstained. hITF-immunopositive cells could be also seen in close proximity to the perivascular spaces of blood vessels within the median eminence. All of these cells additionally showed GFAP immunofluorescence (Fig. 2). Some of the hITF-positive tanycytes extended processes towards the lumen of the third ventricle. They seemed to be associated with the internal layer of the median eminence while other hITF-positive cells were clearly located on the external zone in close apposition to blood vessels. The total number of hITF-immunostained tanycytes represented only a small portion of all the tanycytes in the median eminence.

DISCUSSION

In previous studies, hITF immunoreactivity and its corresponding transcript were observed in the PVN, the PEV and accessory neurons of the human hypothalamus, in Herring Bodies of the neurohypophysis, and in endocrine cells of the adenohypophysis (Probst et al., 1996). Trefoil peptides might represent a novel group of neuropeptides with several different functional properties in hypothalamic neurons. With combined immunofluorescence for either oxytocin (OT) or neurophysin I with immunoperoxidase staining for hITF, almost a 100% coexpression of hITF and OT was observed in magnocellular cells of the PVN and a partial coexistence was observed in the SON (Griepentrog et al., in press). Since OT is a posterior lobe peptide transported through hypothalamic axons and the infundibular stalk, we focused in this study on the area of the median eminence and the infundibulum. Immunocytochemistry and combined immunofluorescence with anti-GFAP antibodies showed both intense hITF- and GFAP-staining of perikarya and processes in cells within this area.

GFAP is an established marker for glial cells. It is known to be the major component of intermediate filaments in differentiated astrocytes and it has also been localized in pituicytes and tanycytes (Redecker et al., 1987; Salm et al., 1982). In view of the morphological characteris-

tics and the GFAP immunoreactivity of these cells, we conclude that these cells must belong to the group of tanycytes, a specialized form of astrocytes, lining the base of the third ventricle. Ependymal cells are linked by gap junctions whereas tanycytes have blood-brain barrier properties, being interconnected with tight junctions. Tanycytes are found in close apposition to hypothalamic neuropeptidergic efferences and to blood vessels of the hypophyseal portal system (Akmayev et al., 1973; Knowles, 1974). They have multiple endfeet to vascular surfaces and in perivascular spaces of the median eminence (Löfgren, 1959; Wittkowski, 1968a). Tanycytes probably play a major role in the linkage of the cerebro-spinal fluid (CSF) and the portal vessels of the pituitary (Wittkowski, 1998). They enclose hypothalamic nerve fibers to control pituitary hormone secretion by neuroglial synaptoid contacts (Kobayashi et al., 1970; Wittkowski, 1968b, 1973). In a previous study, we observed hITF expression in the choroid plexus epithelium, which is known to have a regulatory function on the blood-brain barrier (Probst et al., 1996). hITF was also localized in the basal membrane of blood vessels. We conclude that hITF in tanycytes may be of functional importance for their blood-brain barrier action. Changes in the release activities of neuropeptides from the ME are followed by a remodelling of the neurovascular surface, a process mainly dependent on glial motility (Wittkowski, 1998). hITF expression in tanycytes might be linked to changes in the permeability of the plasma membrane or to changes in glial motility in the median eminence. Most hypothalamic peptides have been shown to have multiple anatomical locations and, consequently, multiple functional properties. Our findings indicate that, similarly, hITF is not only a magnocellular hypothalamic neuropeptide but also a glial factor, perhaps involved in glial plasticity and permeability.

ACKNOWLEDGEMENTS

T.G. is a fellow of the Friedrich-Ebert Foundation. This work was supported by the Deutsche Forschungsgemeinschaft Ji 10/4-2 and Verbund Klinische Forschung der Friedrich-Schiller-Universität, Project B1.

REFERENCES

- AKMAYEV IG, FIDELINA DV, KALSOLOVA ZF, POPOV AP and SCHITKOVA TA (1973). Morphological aspects of the hypothalamo-hypophyseal system. IV. Medial basal hypothalamus. An experimental morphological study. *Z Zellforsch*, 137: 493-512.

- JIRIKOWSKI GF, RAMALHO-ORTIGAO JF and CALDWELL JD (1991). Transitory coexistence of oxytocin and vasopressin in the hypothalamo-neurohypophyseal system of parturient rats. *Horm Metab Res*, 23: 476-480.
- KNOWLES F (1974). Endocrine activity in the central nervous system. In: Bellairs R and Gray EG (eds). *Essays on the Central Nervous System*. Clarendon Press, Oxford, 431-450.
- KOBAYASHI H, MATSUI T and ISHII S (1970). Functional electron microscopy of the hypothalamic median eminence. *Int Rev Cytol*, 29: 282-381.
- LÖFGREN F (1959). New aspects of the hypothalamic control of the adenohypophysis. *Acta Morphol Neerl Scand*, 2: 220-229.
- PODOLSKY DK, LYNCH-DEVANEY K, STOW JL, OATES P, MURGUE M, DE BEAUMONT M, SANDS BE and MAHIDA YR (1993). Identification of human intestinal trefoil factor. *J Biol Chem*, 268: 6694-6702.
- PROBST JC, SKUTELLA T, MÜLLER-SCHMID A, JIRIKOWSKI GF and HOFFMANN W (1995). Molecular and cellular analysis of rP1.B in the rat hypothalamus: in situ hybridization and immunohistochemistry of a new P-domain neuropeptide. *Mol Brain Res*, 33: 269-276.
- PROBST JC, ZETSCHKE T, WEBER M, THEILEMANN P, SKUTELLA T, LANDGRAF R and JIRIKOWSKI GF (1996). Human intestinal trefoil factor is expressed in human hypothalamus and pituitary: evidence for a novel neuropeptide. *FASEB J*, 10: 1518-1523.
- REDECKER P, WITTKOWSKI W and HOFFMANN K (1987). Glial cells positive for glial fibrillary acidic protein in the neurohypophysis of the Djungarian hamster (*Phodopus sungorus*). *Cell Tissue Res*, 249: 465-471.
- SALM AK, HATTON GI and NILAVER G (1982). Immunoreactive glial fibrillary acidic protein in pituicytes of the rat neurohypophysis. *Brain Res*, 236: 471-476.
- SCHIEBLER TH, LERANTH C, ZABORSZKY L, BITSCH P and RÜTZEL H (1978). On the glia of the median eminence. In: Brain-Endocrine Interaction III. *Neural Hormones and Reproduction*. 3rd Int Symp, Würzburg 1977, Karger, Basel, pp 46-56.
- WITTKOWSKI W (1968a). Elektronenmikroskopische Studien zur interventrikulären Neurosekretion in den Recessus infundibularis der Maus. *Z Zellforsch*, 92: 207-216.
- WITTKOWSKI W (1968b). Zur Ultrastruktur der ependymalen Tanyzyten und Pituizyten sowie ihre synaptische Verknüpfung in der Neurohypophyse des Meerschweinchens. *Acta Anat*, 67: 338-360.
- WITTKOWSKI W (1973). Elektronenmikroskopische Untersuchungen zur funktionellen Morphologie des Tuberohypophysären Systems der Ratte. *Z Zellforsch*, 139: 101-148.
- WITTKOWSKI W (1998). Tanycytes and pituicytes: morphological and functional aspects of the neuroglial interaction. *Mikr Res and Tech*, 41: 29-42.