ORIGINAL ARTICLE

Eur J Anat, 15 (3): 140-149 (2011)

Morphometric evaluation and a report on the aberrations of the foramina in the intermediate region of the human cranial base: A study of an Indian population

Namita A. Sharma[1], Rajendra S. Garud[2]

1- Dept of Anatomy, Bharati Vidyapeeth Deemed University, Dental College and Hospital, Pune, India
2- Dept of Anatomy, Bharati Vidyapeeth Deemed University, Medical College and Hospital, Pune, India

Summary

The study of the skull and its foramina is important to anatomists, anthropologists, forensic experts and clinicians. It provides an insight into the evolutionary history of humankind. The dimensions of the foramina and variations in the same are clinically significant in view of the delicate neurovascular structures that traverse them. The present study focuses on the foramina communicating the middle cranial fossa with the base of the human skull. The parameters include the frequency of occurrence of accessory foramina, exocranial dimensions, bilateral symmetry, dominance and any variations in the regular paired foramina, along with their distances from the median plane.

Measurements were taken on fifty dried human skulls of Indian origin. The instrument used was a sliding Vernier caliper with a precision of 0.01mm. Ethnicity being a cause of variation is an interesting concept and was kept in mind while reviewing the work of others along with the observations made in the present study.

Some rare aberrations were noted. One skull showed an ossified pterygospinous ligament and another had a thin bony bar across the foramen ovale. Both findings were unilateral and both would probably cause pressure on the neurovascular structures traversing the foramen ovale with the resultant clinical manifestations. In one skull, the carotid canal was bilaterally absent and the foramina lacera of the same skull were rounded and smooth edged.

Key words: Foramina – Base of human skull – Middle cranial fossa – Variations

Introduction

The foramina of the cranium, their size, symmetry, and variations have long attracted the attention of researchers, many of whom have documented their observations and have contributed to the corpus of knowledge on this topic.

A study of the skull and its foramina provide insight into the evolutionary history of humankind. Of all the hominid fossils that scientists have discovered, the skull provides the richest information, since it has changed dramatically in size and shape during the course of evolution. It is interesting to note that the foramen ovale is consistently absent in the class reptilia and, although this foramen was acquired at the beginning of the appearance of the class mammalia, it is surprisingly

Submitted: April 29, 2011
Accepted: September 2, 2011

Correspondence to:
Dr. Namita Sharma. Department of Anatomy, Bharati Vidyapeeth Deemed University, Dental College and Hospital, Dhanakwadi, PUNE, India 411043. Phone: +91 9216123763. E-mail: drnamitaalok@gmail.com / drnamita@ibibo.com

variable in its presence, even amongst the different members of this class (Edinger and Kitts, 1954). The rodentia constitutes such an order, whose members either possess or lack the foramen ovale (Hill, 1935).The absence of this foramen in some living mammals (including the mammalian embryo, where the semilunar ganglion develops outside the skull anlage and its intracranial position is secondary in ontogeny) led to the theory that a separate mandibular nerve exit is an advanced character developed along the evolution of some orders (Edinger and Kitts, 1954). Such intra-class variability has been noted even in the presence of the foramen lacerum, which was absent in squirrels but present in other rodents dissected by Hill (1935).

Apart from the evolutionary interest they generate, cranial foramina are of clinical significance in view of the neurovascular structures that traverse their narrow confines. Any trauma or space-occupying lesion in this area would result in compressive forces, with the resulting clinical manifestations (Kato et al., 2006). Moreover, knowledge of the variations in the foramina would guide clinicians towards a correct interpretation of radiographs and would be of help in surgical approaches to this complicated region.

The present study aims at noting the metrical and nonmetrical aspects of the paired foramina connecting the middle cranial fossa with

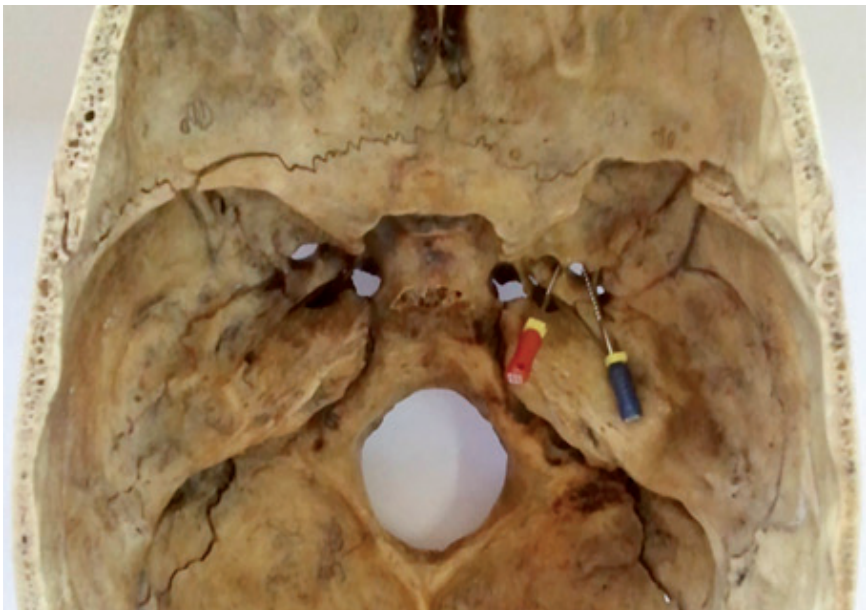

Fig. 1. Bony septation within the foramen ovale.

Fig. 2. An ossified pterygspinous ligament lying immediately external to the foramen ovale.

the skull-base. This includes the variably present foramen of Vesalius and the canalis innominatus and the constant foramina ovale, spinosum and lacerum, as well as the carotid canal. The parameters under which the foramina were studied included the frequency of the presence of accessory foramina, the dimensions and dominance of the regular foramina, and their distances from the mid-sagittal plane. Variations such as confluence and septations were noted. The observations made in our study were then compared with similar work done earlier in different geographical regions of the world.

Variations amongst the foramina due to the racial origin of the skull is an interesting and much debated concept and was kept in mind while comparing and analyzing the observations documented by the different workers, including those made in the present study

Materials and Methods

By convenience sampling, fifty dry, macerated, unsexed adult human crania were collected from the musea of Bharati Vidyapeeth Deemed University, Medical and Dental colleges, Pune, Maharashtra. The skulls were of Indian origin and were all recent, belonging to the latter half of the twentieth century. Their adult status was determined by the synostosis between the basi-occiput and basisphenoid at the cranial base. They were checked for any damage and only those in good condition were selected.

A Vernier caliper with a precision of 0.01 mm was used to measure the diameters on the exocranial aspect of the regular paired foramina connecting the middle cranial fossa with the base of the skull. To minimize error, each measurement was taken twice by the same observer and, in the case of discrepancy, the mean of the two values was noted. If any foramen was found to be too narrow to be measured with the Vernier caliper, its dimensions were judged by whether it allowed an endodontic instrument (K file # 80) to pass through it.

The two diameters of the foramen ovale measured were along its long and short axes. Since this foramen is an obliquely placed oval-shaped foramen, we deemed it fit to term these diameters as the medio-lateral and antero-posterior diameters respectively. It should be noted that these two diameters were perpendicular to each other. For both the foramen lacerum and the carotid canal, the diameters measured were the maximum transverse and antero-posterior diameters, while for the foramen spinosum only the maximum transverse diameter was recorded. For the sake of uniformity, the transverse diameters of the foramina lacerum and spinosum as well as of that of the carotid canal are referred to as the medio-lateral diameter. Any deviation from the normal in terms of shape, size, septation or confluence with adjacent foramina was also recorded.

The mid sagittal plane was marked as a line extending from the schindylesis between the vomeral alae and sphenoidal rostrum to the basion. The distances from the medial edge of the paired regular foramina to the mid-sagittal plane were measured and statistically analyzed using the paired *t* test for any significant difference between the right and left sides. For the purpose of comparison, the size of the foramina was taken as the product of their longest and shortest diameters. The frequency of occurrence of accessory foramina was noted.

Results

The foramen of Vesalius is an occasionally present emissary foramen allowing the passage of an emissary vein connecting the pterygoid venous plexus with the cavernous venous sinus. In the present study it was absent in 19 (38%) skulls, unilaterally present in 4 (8%) and 5 (10%) skulls on the right and left sides respectively, and its bilateral presence was seen in 22 (44%) skulls. In no skull was it seen to be confluent with neighboring foramina such as the ovale or spinosum. No duplication of the foramen was noted in any skull.

The canalis innominatus is an inconstant foramen and, when present, provides an independent exit for the lesser petrosal nerve. In our study it was absent in 34 (68%) skulls, unilaterally present on the right side in 6 (12%), and on the left side in another 6 (12%) skulls. In 4 (8%) skulls it was seen to be present bilaterally.

The foramen ovale was bilaterally present in all skulls. Its dimensions were found to be variable over a wide range (Table 1).

The shape of the foramen was also seen to be variable. While most of the foramina were oval with the long axis along the medio-lateral diameter, in 2 (4%) skulls bilaterally and in1 (2%) skull unilaterally the foramen was oval, but with the long axis along the antero-poste-

Table 1. Metrical data on the foramina ovale, lacerum, carotid canal and spinosum.

Foramen	Mean diameter		Range (mm)		Size (mm)	
	M-L axis	A-P axis	M-L diameter	A-P diameter	Max.	Min.
Ovale	7.05	3.99	3.44-10.80	2.30-9.50	10.80x6.20	5.8x2.3
Lacerum	5.94	8.37	2.80-15.84	4.72-13.34	15.84x7.04	5x2.8
Carotid canal	7.01	5.42	4.50-9.52	3.20-8.14	8.70x8.14	7.14x3.2
Spinosum	2.56	-	Pin-hole sized foramen -4.52		-	-

M-L=Medio-lateral, A-P=Antero-posterior

Table 2. Bilateral difference in size (foramen ovale, carotid canal, foramen spinosum).

Foramen		Difference in size			
		>2mm	>1.5mm	>1mm	>0.5mm
Ovale	M-L diameter	0%		0%	
	A-P diameter	4% (right dominance) 4% (left dominance)	-	6% (right dominance) 18% (left dominance)	-
Carotid canal	M-L diameter	4% (right dominance)	16% (right dominance)	40% (right dominance) 2% (left dominance)	48% (right dominance) 16% (left dominance)
	A-P diameter	4% (right dominance)	6% (right dominance) 2% (left dominance)	14% (right dominance) 10% (left dominance)	26% (right dominance) 18% (left dominance)
Spinosum	M-L diameter	-	6% (right dominance) 4% (left dominance)	20% (right dominance) 2% (left dominance)	34% (right dominance) 18% (left dominance

M-L=Medio-lateral, A-P=Antero-posterior

Table 3. Distance from the medial edge of the paired regular foramina to the mid sagittal plane.

Foramen	Distance from mid sagittal plane- Range (mm)	Distance from mid sagittal plane- Mean (mm)	
		Right (mm)	Left (mm)
Ovale	17 - 25.60	22.13	21.71
Spinosum	23 - 33.90	28.53	28.13
Carotid canal	20.80 - 31	25.31	24.88

rior diameter and 1 (2%) skull unilaterally had a circular foramen with the two axes differing by only 0.01mm.

Only 2 (4%) skulls showed confluence of the foramen ovale with the foramen spinosum-both unilaterally on the left side. No confluence with other foramina was noted.

Abnormal findings observed in one skull showed the right sided foramen ovale having a thin bony septation perpendicular to the long (i.e. medio-lateral) axis of the foramen, dividing the foramen into two compartments of approximately equal size. This septation was intrinsic to the foramen and not a part of any ossified ligament (Fig. 1).

In another skull, a completely ossified pterygospinous ligament passed immediately inferior to the left-sided foramen ovale, effectively leading the exocranial orifice of the foramen to be divided into two bony compartments (Fig. 2). Other metrical data on the foramen ovale are presented in Tables 1-3.

The foramen spinosum was present bilaterally in all the skulls studied. However, one out of the 100 foramina observed was found to be stenosed. This pinhole sized orifice was too

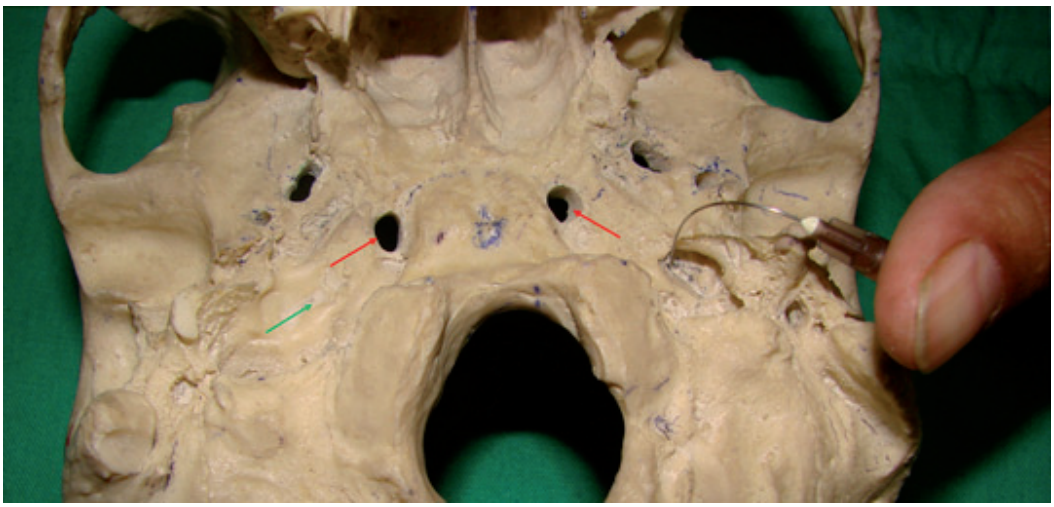

Fig. 3. Red arrows indicate bilaterally present smooth rounded foramina lacera. Green arrow indicates a completely absent right sided carotid canal. Bent needle indicates a blind fossa in lieu of the left-sided carotid canal.

narrow to be measured with the Vernier caliper. It did however, allow the passage of an endodontic instrument, K file # 80.

Confluence of the foramen spinosum with neighboring foramina was an infrequent finding in the present study. The foramen was confluent with the foramen lacerum in 1 (2%) skull on the right side, with the foramen ovale in 2 (4%) skulls, both on the left side, and with the canalis innominatus in 1 (2%) skull on the right side. Other metrical data on the foramen spinosum are presented in Tables 1-3.

The foramen lacerum has been described as a gap between the basiocciput, basisphenoid and the apex of the petrous temporal. The carotid canal opens onto its posterior wall while the pterygoid or the Vidian canal commences from its anterior wall. However, no major structure traverses the canal. In one skull, the foramen was seen to be bilaterally circular, with smooth edges belying its name (Fig. 3).

The metrical data noted while studying the foramen lacerum are presented in Table 1.

In view of its important contents, the size and dominance (in terms of size) of the carotid canal are significant. The dimensions of the canal in the present study were found to vary over a wide range (Table 1). The mean dimensions of both diameters were marginally higher on the right side. In one skull, the right-sided carotid canal was completely absent while on the left side it was represented merely by a blind fossa (Fig. 3). This anomaly of the carotid canal was co-existent with the smooth edged foramen lacerum, as noted above. Other metrical data on the carotid canal are shown in Tables 1-3.

Discussion

The variations in the occurrence, size and location of cranial foramina continue to interest anatomists and clinical scientists for several reasons. Despite the fact that some of the variants could be a consequence of disease or other extrinsic influences, Berry and Berry (1967) have very convincingly cited reasons to believe that most of these aberrations are genetically determined. Hauser and De Stefano (1989) further suggest that these cranial variants may be described as epigenetic since they are products of the genetically determined growth processes of other tissues such as nerves, vessels and muscles, which affect bone formation. Apart from their clinical significance, these variations could be indicative of ethnic differences or evolutionary processes. In fact, some authors believe in the possibility of constructing geographical 'iso-incidence' lines for a particular variant, since they claim that the frequency of a particular variant is found to be constant in a particular ethnicity and similar in related ethnic groups (Berry and Berry, 1967).

It is interesting to note that the foramen of Vesalius is an exclusive feature of the human skull and is not present in any other primate (Wood-Jones, 1931). Observations made in previous studies of this foramen indicate the variability in the frequency of its presence - both unilateral as well as bilateral. In the 39th edition of Gray's Anatomy, Standring et al. (2005) have noted that the foramen is present in 40% of skulls, but without specifying whether this figure refers to its unilateral or bilateral presence, while Ginsberg et al. (1994) found it in as many as 80% of the 123 CT stud-

Table 4. Foramen Ovale: (comparison of data from the present study with the literature).

	Lindblom (1936)	Radoievitch et al. (1956)	Sondheimer (1971)	Lang (1983)	Ginsberg et al. (1994)	Berge&Bergman (2001)	Present Study
Mean size(mm)	7x4	-	-	7.26x3.65	-	7.11x3.60	7.05x3.99
Max. size(mm)	10x4	10x6	-	9.9x9.70	-	8x7	10.80x6.20
Min. size(mm)	6x3	5x1	-	4.2x1.70	-	5x2	5.80x2.30
Confluence with foramen Vesalius	-	-	-	-	7.5%	1% unilaterally	Nil
Confluence with foramen spinosum	-	2%	-	-	1.6%	1% bilaterally 2% unilaterally	4% unilaterally
Pithicoid type of foramen ovale	-	1%	16%	-	-	4% bilaterally 2% unilaterally	Nil
% of skulls with difference in size < 2 mm	-	-	80% (diameter not specified)	-	-	93% (diameter not specified)	100% in medio-lateral diameter 92% in antero-posterior diameter

ies conducted on the temporal bone - this included both its unilateral as well as its bilateral presence. Boyd (1930) and Kodama et al. (1997) found its bilateral presence in only 14.7% and 16.25% of adult skulls respectively, while in the present study it was seen to be bilateral in as many as 44% of skulls, which is close to the observations made by Berge and Bergman, (2001), who found it bilateral in 35% of skulls. Even in the unilateral presence of the foramen the observations are variable, ranging from 24% (Berge and Bergman, 2001), 21.8% (Boyd, 1930), 18% (present study) to only 5.5% (Kodama et al., 1997) of the skulls studied. Unilateral duplication of the foramen as found by Boyd (1930) and Kodama et al. (1997) was not observed in our study.

The frequency of the presence of the canalis innominatus (canal of Arnold) was found to be 20% and 16.3% by Sondheimer (1971) and Ginsberg et al. (1994) respectively while Berge and Bergman (2001) noted its presence in 45% of skulls, in which it was bilateral in only 9%. In our study the canalis was present in 32% of skulls, and of these it was bilateral in 8%.

It is therefore interesting to note that there is very considerable variation across the globe in the frequency of presence of these accessory foramina, and to give a single figure, or even a range indicating such a frequency, would be erroneous.

In view of its important contents, the foramen ovale has attracted the attention of many researchers. In their studies, Lindblom (1936), Radoievitch et al. (1956), Lang (1983) and Berge and Bergman (2001) found great variability in the size of the foramen (Table 4). Similar variations were observed in the present study, in which the size of the foramen ranged between 3.44mm and 10.80mm in the medio-lateral diameter and between 2.30mm and 9.50mm in the antero-posterior diameter. Wood-Jones (1931) and Lindblom (1936) attributed the variability in size to the number of veins that pass through the foramen. Despite the variability in size, Sondheimer (1971), Berge and Bergman (2001) and ourselves in the present study, found a surprisingly large percentage of skulls showing bilateral symmetry in size (with a difference of less than 2 mm) (Table 4). Confluence with the neighboring foramina such as the foramen of Vesalius was not observed in the present study, while confluence with the foramen spinosum was seen unilaterally in 4% of skulls (all on the left side). Similar observations were recorded by Radoievitch et al. (1956), Ginsberg et al. (1994) and Berge and Bergman (2001) (Table 4).

In their extensive study of 585 adult crania from various human 'ethnicities', Berry and Berry (1967) found such an aberration ranging from 0% (in skulls belonging to modern Palestinians) to 8.2% (in Burmese skulls). Interestingly, the incidence of this variation in North Indian skulls as observed in their study was 3.8%, which is similar to the observations made here.

In a study of the skulls of two genera of monkeys, of apes and of various ethnicities of humans, four different types of foramina ovale

were found, ranging from an open notch to a completely closed foramen (Edinger and Kitts, 1954). Interestingly, none of the types were restricted to a single group.

A pithicoid type of foramen ovale (which is partially open to the foramen lacerum and is a frequent feature in apes) was seen in 16% of roentgenograms reviewed by Sondheimer (1971), but in only 1% of skulls studied by Radoievitch et al. (1956), and 4% of skulls bilaterally and 2% unilaterally in the study by Berge and Bergman (2001). No such occurrence was found in the present study of Indian skulls. Berge and Bergman (2001) have attributed these variations between radiologic findings and observations on dry skulls to a roentgenographic artifact.

In the present study, one skull had a thin bony bar bridging across the right sided foramen ovale. This was not a part of either the pterygospinous or pterygoalar ligaments but was intrinsic to the foramen itself. The septation was located on the endocranial aspect and did not traverse the entire depth of the foramen so as to be evident on the external side (Fig. 1).There was no doubt that the anterior portion of the compartmentalized foramen did not qualify as the Vesalius, since the medio-lateral dimension of the entire foramen (including both parts on either side of the septation) was almost equal to that of the contralateral non-septate foramen ovale. Such an occurrence has not been reported previously. Another skull showed a completely ossified pterygospinous ligament extending from the spine of the sphenoid to the base of the lateral pterygoid plate on the left side. This lay flush with the exocranial orifice of the foramen ovale, effectively dividing the foramen into two bony compartments (Fig. 2). In both cases, the partitioning of the foramen ovale might have led to the compression of the mandibular nerve with the resulting neuralgia over the mandibular and preauricular region of the face, together with motor manifestations such as paresis of the muscles developing from the mesoderm of the first branchial arch. In the absence of relevant clinical histories, such correlations could not be confirmed. A complete ossification of the pterygo-spinous ligament (termed the osseous bar of Civinini) is not uncommon. Several authors have reported its presence, ranging from 8.8% (Peker et al., 2002), 8% (Wood-Jones, 1931), 5.76% (Nayak et al., 2007), to only 1.6% (Galdames et al., 2010) in the skulls studied by them. It

Table 5. Foramen Spinosum: (comparison of data from the present study with the literature).

	Lindblom (1936)	Berge & Bergman (2001)	Present Study
Mean size (mm)	Short axis :2	2.39 x 1.96	Medio-lateral diameter: 2.56
Max. size(mm)	3	4 x 3	4.52
Min. size(mm)	1.5	1 x 1	Pin hole sized foramen
Asymmetry >1.5mm	1%	1%	10%
Asymmetry >1mm	2%	2%	22%
Asymmetry >0.5mm	_	15%	52%
Absence	0.4%	1% unilaterally	Nil
Confluence with canalis innominatus	-	bilaterally 1% unilaterally 3%	2% unilaterally
Confluence with foramen lacerum	-	bilaterally 4% unilaterally 9%	2% unilaterally
Confluence with foramen ovale	-	bilaterally 1%bunilaterally 2%	4% unilaterally

Table 6. Carotid Canal: (comparison of data from the present study with the literature).

	Berge & Bergman (2001)	Present Study
Average size(mm)	7.13x5.29	7.01x5.42
Max.size(mm)	12x5	8.7x8.14
Min. size(mm)	5.5x0.64	7.14x3.20
Bilateral difference >0.5mm	23% (diameter not specified)	64% in medio-lateral diameter, 44%-in anteroposterior diameter

is essential to consider the importance of such a bar when attempting any therapeutic procedure in the infratemporal region. Lepp and Sandner (1968) have emphasized the importance of an exploratory radiologic examination of the base of the skull of the patient prior to a surgical approach to this region and we feel that such an investigation is warranted.

The mean medio-lateral diameter of the foramen spinosum in our study was close to that observed by Berge and Bergman (2001) (Table 5). However, in terms of bilateral asymmetry of this foramen, the findings in the present study differed considerably from those of both Lindblom (1936) and Berge and Bergman (2001) (Table 5).

Variations in the foramen spinosum such as its doubling, or absence as noted in 0.4% of roentgenograms studied by Lindblom (1936) and in 1% of skulls studied by Berge and Bergman (2001), were not seen in our study. However we did find one skull which unilaterally had a pinhole sized foramen, which would have been too narrow to accommodate the middle meningeal artery. In such cases, the artery may be a branch of the ophthalmic division of the internal carotid artery. In the present study, unilateral confluence with the foramen ovale was seen in 4% of skulls, with a canalis innominatus in 2% of skulls and with a foramen lacerum in 2% of skulls. These findings are similar to the observations reported by Berge and Bergman (2001) (Table 5). Berry and Berry (1967) have described a variant form of the foramen spinosum as being deficient in its posterior wall. They observed such an aberration ranging between 7.1% (of Nigerian skulls) and 18.9% (of Peruvian skulls). The frequency of such an occurrence in the Indian skulls included in their study was 13.2%.

Probably because it does not transmit any major structure, the foramen lacerum has not been much studied by previous researchers. In the present study its dimensions were seen to vary within a wide range of 2.80-15.84 mm medio-laterally and 4.72-13.34 mm antero-posteriorly (Table 1).

The dimensions of the carotid canal are of paramount importance in view of its contents. The mean dimensions of the carotid canal (exocranial orifice) in the present study were close to the observations made by Berge and Bergman (2001) (Table 6). However, the variations in the size of the foramen were more divergent in the study conducted by them, where the range was between 5.5 x 0.64 mm (smallest) and 12 x 5 mm (largest). The vascular manifestations in the brain of a patient with stenosed canal of this type (with a diameter of 0.64 mm) would have made an interesting study. In the present study no such stenosed foramen was found, the smallest foramen recorded being 7.14 x 3.20 mm. However, bilateral asymmetry in terms of a difference of more than 0.5 mm was found in a much larger percentage of skulls in our study than previously reported (Table 6).

In one skull studied in the present study, a bilateral absence of the carotid canal (CC) was noted (Fig.3). Toth et al. (2006) have reported that the internal carotid artery (ICA) is crucial for the formation of the CC. In the case of agenesis of the ICA, or if the vessel takes an aberrant path, the canal will fail to develop.

Agenesis, aplasia and hypoplasia of the ICA are rare congenital anomalies occurring in less than 0.01% of the population (Given et al., 2001; Nicoletti et al., 2009). Reports of such an anomalies associated with a deficient development of the CC are scattered throughout the literature (Given et al., 2001; Kim et al., 2006; Nicoletti et al., 2009; and Yadav et al., 2009).

An ectopic position of the ICA is a very rare variation (Prokopakis et al., 2008). Those authors classified aberrations in the course of the artery in two distinct categories: tortuosity and kinking. The causes of such variations are either atherosclerosis or a congenital deformity. Aberrant paths of the vessel coursing through the middle ear (Britton, 1988; Shimizu et al., 2009) or presenting as a pulsatile oropharyngeal mass (Wasserman et al.,2006; Prokopakis et al., 2008) have been reported.

In the present case, we feel that the ICA was not only bilaterally present but well formed, and the absence of the canal was due to an aberrant course of the vessel which gained intra-cranial entry via the foramina lacerum. This hypothesis is based on the observations that the foramina lacera of the same skull were perfectly smooth and rounded (as they should be if transmitting a vessel of such stature) and, on either side of the body of the sphenoid, there were distinct carotid grooves, which are only likely to be produced if impressed upon by well formed vessels. To the best of our knowledge, such an aberrant course of the ICA has not been reported.

Given et al. (2001) have stated that agenesis of the ICA could be due to various mechan-

ical/hemodynamic stresses on the embryo, such as exaggerated folding or constriction by amniotic bands. We suspect that a similar insult could lead to an altered course of the artery and a resulting lack of development of the CC.

Despite its rare occurrence, consideration of an ectopic position of the ICA is of utmost importance while planning surgery of the cranial base. Appropriate imaging studies should essentially be done prior to the surgery and an absence of the carotid canals revealed in such investigations should alert surgeons and help prevent an iatrogenic disaster.

In the present study no significant difference was found in the distances from the medial edge of the paired regular foramina to the mid sagittal plane on the right and left sides (Table 3).

In conclusion, many authors have reported ethnic variations in their study of different cranial foramina (Sawyer et al., 1998; Cheng et al., 2006). Here, while reviewing the literature and making a comparative analysis of past and present data, we are unable to define a definite pattern that would endorse foraminal variations linked to the ethnic origin of the skull under study. The frequency of the presence of accessory foramina, such as the Vesalius and innominatus for example, varied within a wide range and, interestingly, for both foramina our observations were similar to those made by Berge and Bergman (2001). It should be noted that our study and that performed by Berge and Bergman (2001) were done on skulls of very different ethnic origins. On the other hand, there is a remarkable uniformity in diversity regarding the observations made on the foramen ovale by workers from different parts of the globe. All have recorded considerable variation in the dimensions of this foramen and yet, paradoxically, a high degree of bilateral symmetry in size of the same foramen has been noted by all.

Thus, the variability in the findings of different authors and the inexplicable similarity in some observations on skulls of distinctly different ethnic origins, forces us to conclude that it is not possible to categorically state that ethnicity would be cause of variations in cranial foramina, and the variations that were noted upon comparing the observations of previous researchers with those made in the present study were purely incidental.

References

Berge JK, Bergman RA (2001) Variations in size and in symmetry of foramina of the human skull. *Clin Anat,* 14: 406-413.

Berry AC, Berry RJ (1967) Epigenetic variation in human cranium. *J Anat,* 101: 361-379.

Boyd GI (1930) Emissary foramina of cranium in man and the anthropoids. *J Anat,* 65: 108-121.

Britton BH (1988) Bruit caused by aberrant carotid artery in the middle ear. *Surg Neurol,* 30: 71-72.

Cheng Aco, Yuen Hkl, Lucas PW, Lam Dsc, So KF (2006) Characterization and localization of the supraorbital and frontal exits of the supraorbital nerve in Chinese: An anatomic study.*Ophthal Plast Reconst Surg,* 22: 209-213.

Edinger T, Kitts DB (1954) The foramen ovale. *Evolution,* 8: 389-404.

Galdames IS, Matamala DZ, Smith RL (2010) Anatomical study of the pterygospinous and pterygoalar bony bridges and foramens in dried crania and its clinical relevance. *Int J Morphol,* 28: 405-408.

Ginsberg LE, Pruett SW, Chen M.Y, Elster AD (1994) Skull-base foramina of the middle cranial fossa: reassessment of normal variation with high resolution CT. *Am J Neuroradiol,* 15: 283-291.

Given II CA, Huang-Hellinger F, Baker MD, Chepuri NB, Morris PP (2001) Congenital absence of the internal carotid artery: Case reports and review of the collateral circulation. *Am J Neuroradiol,* 22: 1953-1959.

Hauser G, DE Stefano GF (1989) Epigenetic variant of the human skull. Schweizebart, Stuttgart.

Hill Je (1935) The cranial foramina in rodents. *Jour Mamm,* 16: 121-129.

Kato H, Kanematsu M, Goshima S, Kondo H, Nishibori H, Tsuge Y, Yokoyama R, Hoshi H, Shiratori Y, Onozuka M (2006) Skull base metastasis from hepatocellular carcinoma revealed by cranial nerve palsy: Reports of two cases. *Eur J Radiol, (Extra)* 54: 1-4.

Kim MS, Lee SJ, Lee CH, Park H II (2006) Bilateral segmental absence of the internal carotid artery with rete compensation associated with absence of basilar artery: case report. *Surg Neurol,* 65: 615-619.

Kodama K, Inoue K, Nagashima M, Matsumura G, Watanabe S, Kodama G (1997) Studies on the foramen Vesalius in the Japanese juvenile and adult skulls.*Hokkaido Igaku Zasshi,* 72: 667-674.

Lang J (1983) Clinical anatomy of the head. Neurocranium, orbit, craniocervical regions. Springer Verlag, Berlin, New York.

Lepp FH, Sandner MO (1968) Anatomic-radiographic study of ossified pterygospinous and "innominate" ligaments. *Oral Surg Oral Med Oral Path,* 26: 244-260.

Lindblom K (1936) A roentgenographic study of the vascular channels of the skull. *Acta Radiol (Suppl),* 30.

Nayak SR, Saralaya V, Prabhu LV, Pai MM, Vadgaonkar R, D'costa S (2007) Pterygospinous bar and foramina in Indian skulls: incidence and phylogenetic significance. *Surg Radiol Anat,* 29: 5-7.

Nicoletti G, Sanguigni S, Bruno F, Tardi S, Malferran G (2009) Hypoplasia of the internal carotid artery: collateral circulation and ultrasonographic findings. A case report. *J Ultrasound,* 12: 41-44.

Peker T, Karakose M, Anil A, Turgut HB, Gulekon N (2002) The incidence of basal sphenoid bony bridges in dried crania and cadavers; their anthropological and clinical significance. *Eur J Morphol,* 40: 171-180.

Prokopakis EP, Bourolias CA, Bizaki AJ, Karampekios SK, Velegrakis GA, Bizakis JG (2008) Ectopic internal carotid artery presenting as an oropharyngeal mass. *Head and Face Med,* 4: 20.

Radoievitch S, Jovanovitch S, Lotritch N (1956) La morphologie du trou ovale et les rapports du nerf maxilaire infe rieur avec le sinus sphenoidal. *Rev Laryngol Otol Rhinol,* 77: 11-19.

Sawyer DR, Kiely ML, Pyle MA (1998) The frequency of accessory mental foramina in four ethnic groups. *Arch Oral Biol,* 43: 417-420.

Shimizu S, Sasahara G, Iida Y, Shibuya M, Numata T (2009) Aberrant internal carotid artery in the middle ear with a deficiency in the origin of the anterior cerebral artery: A case report. *Auris Nasus Larynx,* 36: 359-362.

Sondheimer FK (1971) Basal foramina and canals. In: Newton TH, Potts DG (eds). *Radiology of the skull and brain*. Mosby, St Louis.

Standring S, Ellis H, Hely JC, Johnson D, Williams A (eds.) (2005) Skull and mandible. In: Gray's Anatomy: The anatomical basis of clinical practice. 39th ed. Elsevier Churchill Livingstone, Philadelphia, pp 466.

Toth M, Medvegy T, Moser G, Patonay L (2006) Development of the protympanum. *Ann Anat,* 188: 267-273.

Wasserman JM, Sciafani SJ, Goldstein NA (2006) Intraoperative evaluation of a pulsatile oropharyngeal mass during adenotonsillectomy. *Int J Pediatric Otorhinolaryngol,* 70: 371-375.

Wood-Jones F (1931) The non-metrical morphological characters of the skull as criteria for racial diagnosis. Part I. General discussion of the morphological characters employed in racial diagnosis. *J Anat,* 65: 179-195.

Yadav P, Kumar A, Saili A, Datta V (2009) Congenital hypoplasia of the internal carotid artery. *Ind J Pediatrics,* 76: 1061-1062.