

Variations in origin and branching pattern of hepatic arteries and their clinical significance

Priyanka Sridhar¹, Arole Vasanti², Bharambe Vaishaly²

¹Dr. D.Y. Patil Medical College, Hospital and Research center, Dr D Y Patil University, Pimpri, Pune 411018, Maharashtra, India, ²Dept. of Anatomy, D.Y. Patil Medical College, Hospital and Research center, Pimpri, Pune 411018, Maharashtra, India

SUMMARY

Hepatobiliary surgeries require extensive knowledge of variations in the origin and branching pattern of arteries extending from the coeliac trunk till the cystic artery. This study was aimed at documenting all possible variations observed in the hepatic arterial tree by meticulous dissection of livers in formalin-fixed cadavers. Twenty formalin-fixed cadavers were meticulously dissected to study the hepatic arterial variations.

The common hepatic artery originated from the coeliac trunk, common hepatogastric trunk and common hepatosplenic trunk in 85%, 5%, and 5% respectively. It was absent in 5%. It gave rise to the gastroduodenal and proper hepatic arteries in 85%, trifurcated into gastroduodenal, left and right hepatic arteries in 5%, and left hepatic, right hepatic and cystic arteries in 5%. The proper hepatic artery continued from the common hepatic artery in 85%, and was absent in 15%. It bifurcated into left and right hepatic arteries in 45%, showed a trifurcating pattern in 20% cases, gave rise to 3 separate hepatic branches in 5%, and continued as left hepatic artery alone in 15%. The left hepatic artery originated either from the proper hepatic artery or was a direct continuation of it in 85%, from the common hepatic artery in 10%, and the superior mesenteric artery in 5% cases. It gave rise to the cystic artery in 5%. The right hepatic

artery originated from proper hepatic artery in 70%, abdominal aorta in 5%, coeliac trunk in 10%, superior mesenteric artery in 5%, common hepatic artery trifurcation in 10%, and gave rise to the cystic artery in 80%. The cystic artery was absent in 5%. Some of the findings have been reported in other studies, while some were newly reported in the present study. Knowledge of hepatic arterial variations is necessary to prevent complications involving several specialties including interventional radiology, endovascular surgery, chemotherapeutic procedures, hepatobiliary surgery as well as living donor liver transplantation surgeries.

Key words: Common hepatogastric trunk – Common hepatosplenic trunk – Common hepatic artery – Proper hepatic artery trifurcation – Middle hepatic artery

INTRODUCTION

The hepatic arterial anatomy begins at the coeliac trunk, which originates from the abdominal aorta and gives rise to three branches: namely, the splenic artery, left gastric artery and the common hepatic artery (CHA). The CHA, after giving rise to the gastroduodenal artery, continues as the proper hepatic artery, which then divides into right and left hepatic branches (RHA & LHA respectively), supplying the respective hepatic lobes through several intrahepatic branches. The cystic artery (CA) commonly arises from the RHA, passes posterior to the common hepatic duct and through the middle of the Calot's triangle to supply the gallbladder. The Calot's triangle is bounded medially by the

Corresponding author: Dr Bharambe Vaishaly. Dept. of Anatomy, Dr. D.Y. Patil Medical College, Hospital and Research Center, Pimpri, Pune 411018, Maharashtra, India. Phone: 02025899168; Mobile: 09822910845; Fax: 02027420605. E-mail: vaishalybharambe@yahoo.co.in

Submitted: 12 April, 2019. Accepted: 28 April, 2019.

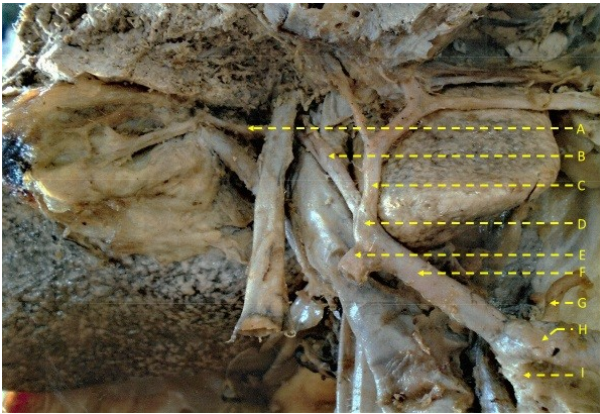


Fig 1. This figure shows the (I) coeliac trunk giving rise to the (H) splenic artery, (G) left gastric artery and the (F) common hepatic artery. After giving rise to the (E) gastroduodenal artery, the common hepatic artery continues as the (D) proper hepatic artery which then divides into the (B, C) right and left hepatic arteries. The cystic artery (A) originates from the right hepatic artery and travels through the Calot's triangle to supply the gallbladder.



Fig 2. Common hepatogastric trunk (G) giving rise to the (E) left gastric artery and the (C) common hepatic artery while the (H) splenic artery arises separately from the abdominal aorta. The main left hepatic artery is a continuation of the (A) proper hepatic artery which in turn continues from the common hepatic artery after the latter gives rise to the (D) gastroduodenal artery. The (I) right hepatic artery originates directly from the abdominal aorta while the (F) accessory left hepatic artery has a separate origin on the hepatogastric trunk. The (B) cystic artery arises from the right hepatic artery within the Calot's triangle and supplies the gallbladder.

common hepatic duct, laterally by the cystic duct and superiorly by the inferior border of the liver (Standring, 2008).

French surgeon and anatomist Claude Couinaud is widely acknowledged for his pioneering work and contributions to hepatobiliary surgery. Sherif Abdel-Misih and Mark Boomston, in their study on the anatomy of the liver, refer to Couinaud's earlier work titled *Foie: Études anatomiques et chirurgicales* (The Liver: Anatomic and Surgical Studies). According to Couinaud, hepatic surgery is entirely an anatomical exercise. He demonstrated that

mere knowledge of external surface anatomy does not suffice in hepatic surgeries. Thorough understanding of the vascular and biliary anatomy, which form the basis of hepatic functional anatomy, is essential (Abdel-Misih and Bloomston, 2010).

The hepatobiliary and pancreatic systems are subject to a vast number of medical and surgical procedures in lieu of the many pathological conditions associated with these systems. Gallstone



Fig 3. Common hepatosplenic trunk (C) giving rise to the splenic artery and common hepatic artery. The (B) gastroduodenal artery originates from the common hepatic artery and the latter then continues as the (A) proper hepatic artery which enters the liver as the main left hepatic artery; while an (E) accessory left hepatic artery originates as a separate branch from the common hepatosplenic trunk. The (D) stump of the left gastric artery can also be seen on the hepatosplenic trunk. The (F) right hepatic artery originates from the superior mesenteric artery and travels through the Calot's triangle, giving rise to the (G) cystic artery which supplies the gallbladder.

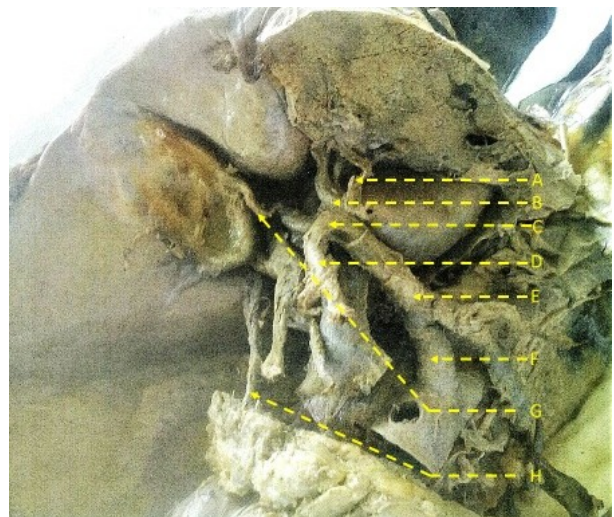


Fig 4. Here the common hepatic artery (E) originating from the (F) coeliac trunk, giving rise to the (D) gastroduodenal artery and then (C) trifurcating into (A) left hepatic artery, (B) right hepatic artery and (G) cystic artery. The (H) accessory right hepatic artery originates from the superior pancreaticoduodenal artery and enters the right lobe of the liver.

Table 1. Table depicting variations in branching pattern of coeliac trunk in relation to CHA.

		Percentage	Number of
1	Coeliac trunk giving rise to splenic artery, left gastric artery and CHA	80%	16
2	Coeliac trunk arising as a common hepatogastric trunk (which further divided into left gastric artery & CHA). The splenic artery arises separately from the abdominal aorta while an accessory LHA takes its origin on this common trunk. [Fig. 2]	5%	1
3	Coeliac trunk arising as a common hepatosplenic trunk (which divided into splenic artery and CHA). The left gastric artery and an accessory left hepatic artery have separate points of origin on this common trunk [Fig. 3].	5%	1
4	Coeliac trunk giving rise to splenic artery, left gastric artery, CHA and RHA (quadfurcation of coeliac trunk)	5%	1
5	Coeliac trunk giving rise to splenic artery, left gastric artery and RHA- In this body the RHA originated from the coeliac trunk and the LHA from the superior mesenteric artery. In the same body the origin of the coeliac trunk and the superior mesenteric artery were found adjacent to each other on the abdominal aorta [Fig. 6].	5%	1

diseases have shown an upward trend lately due to changing lifestyle and dietary habits, thereby increasing the incidence of endoscopic retrograde cholangiopancreatography procedures and cholecystectomies performed to treat the same. Congenital anomalies such as choledochal cyst, though rare, still require surgical management should they occur in a patient. The liver offers a fertile bed for harboring infections and infestations, due to its highly vascular nature. Portal hypertension and its many complications may require surgical modalities of treatment where medical therapies fail. Chronic pancreatitis is an equally common clinical entity with the rising incidence of alcohol consumption and gallstone diseases. Carcinoma of the gallbladder is the fifth most common cancer and the most common cancer of the biliary tree, while adenocarcinoma of the pancreas is the most common malignancy of the pancreas; and both conditions require surgical resection as the main curative treatment option (Rajagopalan, 2012; Min-Jie et al., 2013). Anatomical variations involving the origin and branching patterns of the arterial tree from the coeliac trunk till the cystic artery are very common, with incidences of 9.5%, 38.2%, and 11% for the coeliac trunk (Mburu et al., 2010; Ugurel et al., 2010; Osman and Abradou, 2016), 25.8%, 35.5%, and 48% for the hepatic arteries (Todo et al., 1987; Ugurel et al., 2010; Ahmed et al., 2016); and the cystic artery showed variant origins in 7.5% and 20.7% cases (Aristotle, 1999; Dandekar and Dandekar, 2016). Therefore, knowledge of these variations is of great surgical relevance to prevent complications involving hepatobiliary and pancreatic surgeries.

The objective of this study was to carefully observe and document the variations seen in the origin and branching pattern of the hepatic arterial tree by meticulous dissection of livers in formalin-

fixed cadavers.

MATERIALS AND METHODS

After prior Institutional ethical committee clearance, twenty formalin-fixed cadavers from the anatomy department were taken and meticulous dissection was performed. These cadavers had ages ranging from 18 to 50. The authors are unable to reveal their names and genders, as they were cadavers donated by a voluntary body donation program that involves confidentiality.

In each cadaver, the stomach was removed taking care of the coeliac trunk, and the inferior border of the liver was cut to expose the Calot's triangle to dissect and visualise the arterial pattern properly. The coeliac trunk was identified on the abdominal aorta, and the course of its branches were traced until the origin of the cystic artery. All the variations observed in the present study were noted, and specimens were photographed.

RESULTS

Two cadavers were found to be having a normal arterial anatomy from the coeliac trunk till the cystic artery (Fig. 1).

Table 1 depicts the observations in branching pattern of coeliac trunk in relation to CHA.

Thus it was observed that the CHA took origin from Coeliac trunk directly in 85% (17/20) of the cadavers, from common hepatogastric trunk in 5% (1/20), from common hepatosplenic trunk in 5% (1/20), and was found to be absent in 5% (1/20) of the cadavers. In this body the RHA was directly a branch of the coeliac trunk, and the LHA was a branch of the superior mesenteric artery. Also, in the body with the absent CHA, the coeliac trunk and the superior mesenteric artery were found ad-

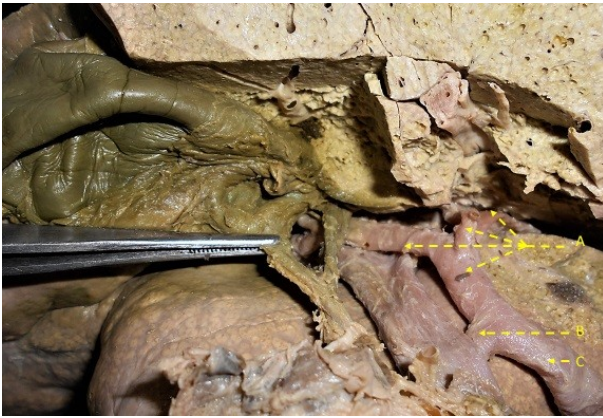

Fig 5. The common hepatic artery (C) is giving rise to (B) gastroduodenal artery and then continuing as the (A) proper hepatic artery which in turn divides into left hepatic, intermediate hepatic and right hepatic artery.

adjacent to each other on the abdominal aorta (Figs. 2, 3, 6).

The CHA showed the following types of branching patterns. The CHA gave origin to gastroduodenal artery and continued as proper hepatic in 85% (17/20) of the cadavers. In one of these bodies the CHA gave rise to two gastroduodenal arteries; and in another body, it gave an additional branch to the common hepatic duct. The CHA was seen trifurcating into gastroduodenal artery, LHA and RHA in 5% (1/20) of the cadavers and it trifurcated into LHA, RHA and cystic artery in 5% (1/20) of the cadavers (Fig. 4). As observed earlier, in 5% (1/20) cadavers, the CHA was found to be absent (Fig. 6).

The proper hepatic artery originated as a continuation of CHA after it gave rise to the gastroduodenal artery in 85% (17/20) of the cadavers. It was absent in 15% (3/20) of the cadavers. In one of these 3 cases it was absent due to an absence of the CHA (where the RHA was a branch of the coeliac trunk and the LHA was a branch of the SMA), and in the remaining two due to the CHA trifurcating into gastroduodenal, LHA, RHA and LHA, RHA and cystic arteries respectively.

Regarding the branching pattern of the proper hepatic artery, which was observed in 85% (17/20) of the cadavers, it was seen to be bifurcating into LHA and RHA in 45% (9/20) of the cadavers, and trifurcating into LHA, middle hepatic artery and RHA in 15% (3/20) of the cadavers (Fig. 5). It trifurcated into LHA, RHA and cystic artery in 5% (1/20), and gave rise to 3 separate branches namely LHA, middle hepatic artery and RHA in another 5% (1/20) of the cadavers. The proper hepatic artery continued as the main LHA in 15% (3/20) of the cadavers.

In one of these cadavers, the RHA was found to be a branch of the abdominal aorta, and in the other it was a branch of the superior mesenteric artery (Figs. 2, 3). In the 3rd cadaver, the left hepatic artery continuing from the proper hepatic artery, fur-

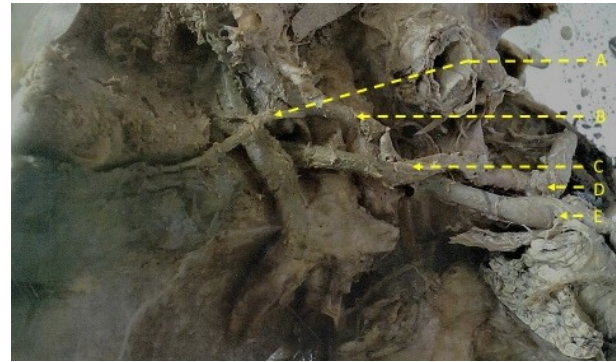


Fig 6. This figure shows the (D) coeliac trunk and (E) superior mesenteric artery originating side by side on the abdominal aorta. The (C) right hepatic artery originates from the coeliac trunk while the (B) left hepatic artery originates from the superior mesenteric artery and then gives rise to the (A) cystic artery.

ther divided into three hepatic branches and entered the left lobe of the liver. In this case the RHA was a direct branch of the coeliac trunk.

The LHA was found to be a branch of proper hepatic artery in 70% (14/20) of the cadavers. It was a continuation of the proper hepatic artery in 15% (3/20) of the cadavers. In two of these bodies there was also an accessory LHA taking origin from the coeliac trunk (Figs. 2, 3). The course of the RHA in these three cadavers is as described above. The LHA took origin from the CHA trifurcation in 10% (2/20) of the cadavers. As observed earlier, in one of the bodies the CHA trifurcated into gastroduodenal, LHA, RHA and in the other into LHA, RHA and cystic arteries (Fig. 4). The LHA was a direct branch of the superior mesenteric artery in 5% (1/20) of the cadavers (Fig. 6). The LHA divided into two or more smaller hepatic branches in 95% (19/20) of the cadavers and gave rise to cystic artery in 5% (1/20) of the cadavers (Fig. 6).

The RHA took origin as a branch of the proper hepatic artery in 70% (14/20) of the cadavers. In one of these bodies there was also an accessory RHA taking origin from the superior mesenteric artery. The RHA took origin from the abdominal aorta in 5% (1/20), from the coeliac trunk in 10% (2/20) and from CHA trifurcation in 10% (2/20) of the cadavers. In the body showing CHA trifurcation, there was an accessory RHA from the superior pancreaticoduodenal artery (Figs. 2, 6, 4). The RHA took origin from the superior mesenteric artery in another 5% (1/20) of the cadavers (Fig. 3). Thus, two accessory RHAs were observed in the present study, one originating from the superior mesenteric artery and the second from the superior pancreaticoduodenal artery. The RHA gave rise to cystic artery and other smaller hepatic branches in 80% (16/20) of the cadavers. In 20% (4/20) of the cases it gave rise to only two or three hepatic branches. The origin of the cystic artery in these 4 cases is detailed with cystic artery.

The cystic artery was seen taking origin from

RHA in 80% (16/20) of the cadavers. In one of these bodies double cystic arteries were observed, in which both the arteries came from different parts of the same RHA. In another body, it was observed that an accessory cystic artery arose from an accessory RHA, which arose from the superior mesenteric artery. The cystic artery took origin from proper hepatic artery trifurcation in 5% (1/20) and from CHA trifurcation (LHA, RHA and cystic artery) in another 5% (1/20) of the cadavers. It arose from LHA in 5% (1/20 cadavers), and was absent in 5% (1/20) of the cadavers. In this body it was assumed that the gallbladder was supplied by intrahepatic branches from the liver bed.

DISCUSSION

The present study describes the hepatic artery and its branches from their point of origin in the coeliac trunk. It notes any variations in the origin or branching pattern. While many findings reported in the present study have been reported earlier, there are a few which have been mentioned for the first time in this study.

In the present study, the origin of the coeliac trunk and the superior mesenteric artery from the abdominal aorta were found very close to each other in 5% (1/20) of the cadavers. A similar finding was reported by Pulakunta et al. (2008) in a 43-year-old male cadaver. During X-ray angiography and catheter insertion, knowledge of the relative distance indexes and the position of the arteries on the abdominal aorta may help reduce the probability of iatrogenic injuries to the patient (Takahashi et al., 2013; Araujo Neto et al., 2015). The coeliac artery and the superior mesenteric artery are both used as landmarks for locating the position of the renal artery, and this is important when carrying out procedures such as diagnostic arteriography and endovascular interventions for various vascular diseases (Pennington and Soames, 2005). A variation in position of these arteries could be misleading in the above procedures.

During the 4th week of intrauterine life, four ventral splanchnic roots arise from the abdominal aorta to supply the yolk sac. These arterial roots are connected to each other via longitudinal ventral anastomoses running parallel to the abdominal aorta. Eventually the first, second and third roots fuse with each other to form the coeliac trunk with the three usual branches of the coeliac trunk – the splenic artery, left gastric artery and the common hepatic artery arising at the longitudinal anastomosis. The fourth root forms the superior mesenteric artery, which remains connected to the first three fused roots via the longitudinal anastomosis. If there is any deviation in this process of fusion, and if the separation occurs at a higher level than normal, then one of the branches of the coeliac trunk may arise from the superior mesenteric artery, im-

plying that we may get a bifurcation pattern that may present as a common hepatosplenic or common hepatogastric trunk (Malnar et al., 2010; Prakash et al., 2012; Torres et al., 2015; Sangari and Mtui, 2016).

In the present study, the coeliac trunk was seen arising as a common hepatogastric trunk in 5% (1/20) of the cadavers, and there was also an accessory left hepatic artery originating from this trunk. A study by Osman and Abdrabou (2016) reported this in 0.6% cases. Their study reported the Uflacker classification of coeliac trunk variations, wherein the hepatogastric trunk as observed in the present study was classified as type III. Just like in this study, the splenic artery did not originate from the coeliac trunk, but separately from the abdominal aorta in close relation to the common hepatogastric trunk. However, there was no accessory LHA seen arising from the hepatogastric trunk. The authors state that it is important to know the normal and variant vascular anatomy before any surgical interference for treatment of benign and malignant disease of the foregut and midgut, as well as for liver transplantation and aortic vascular surgeries.

The present study reports the coeliac trunk arising as a common hepatosplenic trunk, which also gave rise to an accessory left hepatic artery in 5% (1/20) of the cadavers. In a previous study by Mburu et al. (2010), this finding was reported in 13.1% of the Kenyan population, but there was no finding of an accessory LHA. The present study reports a lower incidence of this variation compared to that reported by Mburu et al. (2010).

A study conducted by Sangari and Mtui (2016) reported that in an 80-year-old cadaver, both a common hepatosplenic and a common hepatogastric trunk were seen taking origin from the abdominal aorta. The common hepatosplenic trunk divided into the common hepatic artery (terminating as the gastroduodenal and right hepatic arteries) and splenic artery and the common hepatogastric trunk divided into the replaced left hepatic artery and left gastric artery. While there was no observation of an accessory left hepatic artery from either of the two trunks, there was however the finding of the left inferior phrenic artery taking its origin from the common hepatic artery and the oesophageal arteries arising from the replaced left hepatic artery to supply the lower end of the oesophagus. These findings stress the importance of prior visualisation of the hepatic arterial anatomy using diagnostic angiography, necessary for procedures such as hepatic arterial infusion chemotherapy, wherein one would have to place two separate catheters because of the differing origins of the right and left hepatic arteries.

The left inferior phrenic artery arising from the common hepatic artery supplied the diaphragm and gave rise to the superior suprarenal artery, which supplied the left adrenal gland. While per-

forming surgical interventional procedures involving the common hepatic artery, awareness of the existence of such a variation can help preserve arterial supply to the diaphragm and the left adrenal gland. The authors also stressed the fact that, if a need arises to ligate the left gastric artery during surgical procedures and one isn't mindful of the possibility of a common hepatogastric trunk giving rise to left hepatic artery, there could be ischaemic damage to the left lobe of the liver.

As mentioned above, the finding of an accessory left hepatic artery was obtained in 10% (2/20) cadavers – one from the common hepatosplenic and the other from the common hepatogastric trunk. Sankar et al. (2011) reported finding an accessory left hepatic artery from the common hepatogastric trunk in a 51-year-old male cadaver, which also had a common hepatosplenic trunk from which the main left hepatic artery eventually took origin – from the proper hepatic artery within the course of this trunk. The finding of an accessory left hepatic artery from the common hepatosplenic trunk in this study bore some similarity to the finding of an accessory hepatic artery from the common hepatosplenic trunk in 5% (2/40) of the cadavers dissected in a study by Olewnik et al. (2017); but here it was an accessory right hepatic artery instead of an accessory left hepatic artery. One plausible importance of such a finding as mentioned by Sankar et al. (2011) is the maintenance of arterial supply to the respective lobe of the liver via such accessory hepatic arteries in case of obstructions involving the common hepatic or the proper hepatic arteries.

In the present study the proper hepatic artery was absent in 15% (3/20) of the cadavers. This was either due to absent CHA or due to trifurcation of CHA into gastroduodenal, LHA, RHA and LHA, RHA, cystic arteries respectively. The case of the absent CHA showed the arterial supply of the liver to be derived from two different sources – the RHA from the coeliac trunk and the LHA from the superior mesenteric artery. A similar finding was reported by Gurgacz et al. (2011), who mentioned of a cadaveric liver receiving arterial supply from three different sources (hence the absence of proper hepatic artery was seen here as well) – namely LHA arising from the left gastric artery, RHA arising from the superior mesenteric artery and middle hepatic artery arising from the CHA, in turn a branch of the common hepatosplenic trunk. Trifurcating CHA is a finding that has been deemed rare, as reported by Badagabettu et al. (2012, 2016) in two separate cadaveric studies conducted, and in both studies the CHA trifurcated into gastroduodenal artery, LHA and RHA. The study conducted by Gurgacz et al. (2011) reports of the CHA trifurcating into gastroduodenal artery, LHA and right gastric artery. All the three studies reported the absence of a proper hepatic artery due to such findings obtained. Even if the trifurcating pattern of

CHA is detected by computerised tomography, the varied branching pattern makes hepatic arterial infusion chemotherapy a difficult technique to conduct (Badagabettu et al., 2012).

The present study reported the proper hepatic artery trifurcating in 20% (4/20) of the cadavers. In one body it was found to divide into left hepatic, right hepatic and cystic arteries. In three bodies it was found to divide into left hepatic, middle hepatic and right hepatic arteries. In a previous study by Michels (1966), it was reported that the middle hepatic artery originated from the proper hepatic artery (though not as a trifurcation of the proper hepatic artery) in 10% cases. The present study reports a 15% incidence of the middle hepatic artery while in a cadaveric study by Jin et al. (2008), the proper hepatic artery gave rise to the middle hepatic artery in 4.8% of the cases studied. This artery is said to supply the segment IV of the liver as per Couinaud's classification, and hence is often referred to as the segment IV artery. Identifying the middle hepatic artery is important during the hepatic resection surgeries, and accidental damage to the artery may result in ischaemic cholangiopathy and hepatic artery thrombosis (Alghamdi et al., 2017). The importance of the middle hepatic artery has increased in last few years because of increase in the number of living donor liver transplantations as well as split liver transplantations wherein an intraoperative damage to this artery may cause ischaemic necrosis in the donor liver hampering donor safety (Jin et al., 2008; Alghamdi et al., 2017).

The present study found the origin of the main RHA from the superior mesenteric artery in 5% and origin of the accessory RHA from the superior mesenteric artery in 5% (1/20) of the cadavers. In a previous study by Sureka et al. (2013), the RHA arose from the superior mesenteric artery in 13.5% patients and the accessory RHA arose from superior mesenteric artery in 3.5% patients. Besides being of importance in liver transplant surgeries, these variations are also important in surgeries related to malignancies of the head of pancreas. The author states that these patients may already be jaundiced, and since the anomalous RHA courses posterior to the portal vein, care needs to be taken to preserve this artery to preserve the arterial supply to the liver and prevent liver necrosis.

The present study reports of double cystic arteries in 5% (1/20) of the cadavers, with both the cystic arteries originating separately from various parts of the same RHA within the Calot's triangle. Double cystic arteries have been reported by Ding et al. (2007) (12.2%), Polguj et al. (2014) (in one 73-year-old male cadaver) and Dandekar and Dandekar (2016) (28%). The finding of double cystic arteries in this study falls in Group I of Ding et al. (2007), laparoscopic classification of cystic arterial anatomy in which the cystic artery passes

through the Calot's triangle. A single cystic artery usually divides into superficial and deep branches at the gallbladder neck. When the deep branch is not visualised during surgery, it should arouse suspicion of the presence of another cystic artery, as often double cystic arteries are associated with congenital absence of deep branch of cystic artery. Often, this second cystic artery is detected only when it starts to bleed (Ding et al., 2007; Polguj et al., 2014; Dandekar and Dandekar., 2016).

This study reports of only hepatic arterial variations and no correlation has been made with any other arterial systems. However, an interesting observation has been made by Ugurel et al. (2010), wherein they found a statistically significant correlation between hepatic and renal arterial variations as observed in 27 out of 42 patients with renal artery variations. Whilst the development of these two organs are independent of each other, anomalous migration of the liver and the kidney during foetal life can trigger an aberration in the visceral and lateral supplying branches of the abdominal aorta. Hence the authors emphasize the importance of using angiographic studies to detect arterial variations prior to any surgical or interventional procedures, and advise that any variation observed in one arterial system should necessitate the search for variations in related arterial systems.

Numerous arterial variations were obtained in this study, some having been reported in previous studies but some such as the two mentioned below have been reported for the first time.

The proper hepatic artery was seen continuing directly as LHA and entering the left lobe of the liver in 15% (3/20) of the cadavers. Kumar et al. (2016) have reported a case of hepatic artery proper continuing as the RHA; it failed to give rise to LHA, which was seen originating from left gastric artery. The authors mention that such aberrant supply to the liver is of great relevance during liver transplant surgeries.

In 5% (1/20) cadavers, an accessory RHA was seen originating from the superior pancreaticoduodenal artery in 5% (1/20) of the cadavers. Here the main RHA took origin from the CHA trifurcation.

The above two findings of proper hepatic artery continuing as left hepatic artery and origin of accessory RHA from the superior pancreaticoduodenal artery have, to the best of our knowledge, not been reported before.

CONCLUSION

Endovascular interventions, diagnostic arteriography and infusional chemotherapy are a few procedures which can become difficult in the presence of an aberrant arterial anatomy. It is important for a surgeon to judge whether an artery is

replaced (supplying the whole liver lobe) or accessory (supplying a part of the liver lobe). This is especially important during transplant surgeries as any wrong ligation can lead to segmental or liver lobe necrosis (Arnold et al., 1991; Weiglein, 1996).

A sound knowledge of hepatic and cystic arterial variations is also necessary for surgeons during cholecystectomy procedures to prevent iatrogenic injuries in this region and conversion of laparoscopic to open cholecystectomy thereby reducing mortality and morbidity due to intra and postoperative complications (Kavitha, 2015).

EXPERIENCE OF THE PERSONS WHO PERFORMED THIS STUDY

This study was a "short term studentship" project selected and sanctioned by the Indian council of medical Research (ICMR). Such projects give the researchers a period of around 3 months in which to complete the study. While carrying out the research the authors found themselves developing great insight into the subtleties and nuances of dissecting around a small space. Given the short period of time, the sample size was limited to 20 cadavers. The authors were motivated to pursue this topic owing to its immense clinical significance, spreading across interventional radiological and surgical procedures alike. Such a dissection was relatively new to some of us as a detailed study in and around the hepatobiliary region was not a part of the undergraduate course material. The authors experienced that there was very little space to carry out this dissection due to presence of other related viscera in situ and gave the researchers an idea about challenges faced by surgeons when operating in such limited space. The authors learnt to apply their theoretical knowledge to identify structures as well as label the variant arteries and developed their dissecting skills. They were finally rewarded to observe findings they had read so much about and also found some new ones to add to the existing wealth of information present on this subject matter!

LIMITATIONS OF THE STUDY

This research was conducted as part of the Indian Council of Medical Research, Short Term Studentship program. The authors were given only three months to carry out this work. Hence the sample size was limited to only 20 cadavers, dissection of which was most suitable to achieve the set target in the given time. Thus the present study has limitation of sample size. In future similar study could be carried out with a larger sample size. The findings in present study could also be researched using more advanced methods of study available in recent times, such as use of contrast media in

angiographic analysis.

ACKNOWLEDGEMENTS

The authors are very grateful for the immense help and guidance given by Dr Vatsalaswamy Puranam, Managing Director, Dr D Y Patil Medical College, Hospital and Research Centre, Pune. A special thanks is also due to Dr P Sonje for her timely guidance.

REFERENCES

- ABDEL-MISIH SRZ, BLOOMSTON M (2010) Liver Anatomy. *Surg Clin N Am*, 90: 643-653.
- ALGHAMDI T, VIEBAHN C, JUSTINGER C, LORF T (2017) Arterial blood supply of liver segment IV and its possible surgical consequences. *Am J Transplant*, 17: 1064-1070.
- ARAUJO NETO SA, FRANCA HA, DE MELLO JR CF, SILVA NETO EJ, NEGROMONTE GR, DUARTE CM, CAVALCANTI NETO BF, FARIAS RD (2015) Anatomical variations of the celiac trunk and hepatic arterial system: an analysis using multidetector computed tomography angiography. *Radiol Bras*, 48(6): 358-362.
- ARISTOTLE S (1999) Variations in origin and course of cystic artery and its relations to Calot's triangle with its clinical implications. *OA Anatomy*, 2(2): 17.
- ARNOLD MM, KREEL L, LO YF, LAW H (1991) Are the hepatic arteries "end arteries"? *Invest Radiol*, 26: 337-342.
- BADAGABETTU SN, PADUR AA, KUMAR N, REGHUNATHAN D (2016) Absence of the celiac trunk and trifurcation of the common hepatic artery: a case report. *J Vasc Bras*, 15(3): 259-262.
- BADAGABETTU SN, SUDARSHAN S, VENU MADHAV N, SIRASANAGANDLA SR (2012) Unusual branching pattern of common hepatic artery – a case report. *Int J Anat Var*, 5: 126-127.
- DANDEKAR U, DANDEKAR K (2016) Cystic artery: Morphological study and surgical significance. *Anat Res Int*, Article ID 7201858.
- DING YM, WANG B, WANG WX, WANG P, YAN JS (2007) New classification of the anatomic variations of cystic artery during laparoscopic cholecystectomy. *World J Gastroenterol*, 13(42): 5629-5634.
- GURGACZ AM, HORBACZEWSKA A, KLIMEK-PIOTROWSKA W, WALOCHA J (2011) Variations in hepatic vascularisation: lack of a proper hepatic artery. Two case reports. *Folia Morphol*, 70(2): 130-134.
- JIN GY, YU HC, LIM HS, MOON JI, LEE JH, CHUNG JW, CHO BH (2008) Anatomical variations of the origin of the segment 4 hepatic artery and their clinical implications. *Liver Transpl*, 14(8): 1180-1184.
- KAVITHA KAMATH B (2015) Dual cystic arteries in association with caterpillar hump of right hepatic artery- a case report and its surgical relevance. *J Clin Diagn Res*, 9(7): AD01-02.
- KUMAR N, SWAMY R, BADAGABETTU SN, PATIL J, PADUR AA P (2016) Multiple branching variation of celiac trunk with clinical importance: a case report. *RJPBCS*, 7(3): 1354-1358.
- MALNAR D, KLASAN GS, MILETIC D, BAJEK S, VRANIC TS, ARBANAS J, BOBINAC D, COKLO M (2010) Properties of the celiac trunk – anatomical study. *Coll Antropol*, 34(3): 917-921.
- MBURU KS, ALEXANDER OJ, HASSAN S, BERNARD N (2010) Variations in the branching pattern of the celiac trunk in a Kenyan population. *Int J Morphol*, 28 (1): 199-204.
- MICHELS NA (1966) Newer anatomy of the liver and its variant blood supply and collateral circulation. *Am J Surg*, 112(3): 337-347.
- MIN-JIE YANG, SU-LI, YONG-GUANG LIU, NA JIAO, JING-SHAN GONG (2013) Common and unusual CT and MRI manifestations of pancreatic adenocarcinoma: a pictorial review. *Quart Imaging Med Surg*, 3(2): 113-120.
- OLEWNIK L, WYSIADECKI G, POLGUJ M, WASNIEWSKA A, JANKOWSKI M, TOPOL M (2017) Types of coeliac trunk branching including accessory hepatic arteries: a new point of view based on cadaveric study. *Folia Morphol*, 76(4): 660-667.
- OSMAN AM, ABDRABOU A (2016) Celiac trunk and hepatic artery variants: A retrospective preliminary MSCCT report among Egyptian patients. *Egyptian J Radiol Nuclear Med*, 47 (4): 1451-1458.
- PENNINGTON N, SOAMES RW (2005) The anterior visceral branches of the abdominal aorta and their relationship to the renal arteries. *Surg Radiol Anat*, 27 (5): 395-403.
- POLGUJ M, PODGÓRSKI M, HOGENDORF P, TOPOL M (2014) Variations of the hepatobiliary vasculature including coexistence of accessory right hepatic artery with unusually arising double cystic arteries: case report and literature review. *Anat Sci Int*, 89(3): 195-198.
- PRAKASH, RAJINI T, MOKHASI V, GEETHANJALI BS, SIVACHARAN PV, SHASHIREKHA M (2012) Coeliac trunk and its branches: anatomical variations and clinical implications. *Singapore Med J*, 53(5): 329-331.
- PULAKUNTA T, POTU BK, GORANTLA VR, VOLLALA VR, JENCY T (2008) Surgical importance of variant hepatic blood vessels: a case report. *J Vasc Bras*, 7 (1): 84-86.
- RAJAGOPALAN S (2012) Hepatobiliary and pancreatic disorders. *Med J Armed Forces India*, 68(3): 209-210.
- SANGARI SK, MTUI EP (2016) Hepatosplenic and left hepatogastric trunks as variant arteries of foregut - A case report. *Int J Anat Var*, 9: 50-52.
- SANKAR KD, BHANU PS, SUSAN PJ (2011) Variant anatomy of the celiac trunk and its branches. *Int J Morphol*, 29(2): 581-584.
- STANDRING S (2008) *Gray's Anatomy*. 40th ed. Churchill Livingstone Elsevier, Spain, pp 1179-1180.
- SUREKA B, MITTAL MK, MITTAL A, SINHA M, BHAMBRI NK, THUKRAL BB (2013) Variations of celiac axis, common hepatic artery and its branches in 600 patients. *Indian J Radiol Imaging*, 23(3): 223-233.
- TAKAHASHI T, TAKEUCHI K, ITO T, ITOH M (2013) Positional relationships among the celiac trunk, superi-

or mesenteric artery, and renal artery observed from the intravascular space. *Surg Radiol Anat*, 35: 411-417.

TODO S, MAKOWKA L, TZAKIS AG, MARSH JW JR, KARRER FM, ARMANY M, MILLER C, TALLENT MB, ESQUIVEL CO, GORDON RD, IWATSUKI S, STARZL TE (1987) Hepatic artery in liver transplantation. *Transplant Proc*, 19(1 Pt 3): 2406-2411.

TORRES K, STAŚKIEWICZ G, DENISOW M, PIETRZYK L, TORRES A, SZUKAŁA M, CZEKAJSKA-CHEHAB E, DROP A (2015) Anatomical variations of the coeliac trunk in the homogeneous Polish population. *Folia Morphol*, 74(1): 93-99.

UGUREL MS, BATTAL B, BOZLAR U, NURAL MS, TASAR M, ORS F, SAGLAM M, KARADEMIR I (2010) Anatomical variations of hepatic arterial system, coeliac trunk and renal arteries: an analysis with multidetector CT angiography. *Br J Radiol*, 83(992): 661-667.

WEIGLEIN AH (1996) Variations and topography of the arteries in the lesser omentum in humans. *Clin Anat*, 9: 143-150.